Gigt tilstande i bagfoden.

Adam Prastowski

fod&ankel sektor

Ortopædkirurgisk afd.

Aalborg Universitetshospital

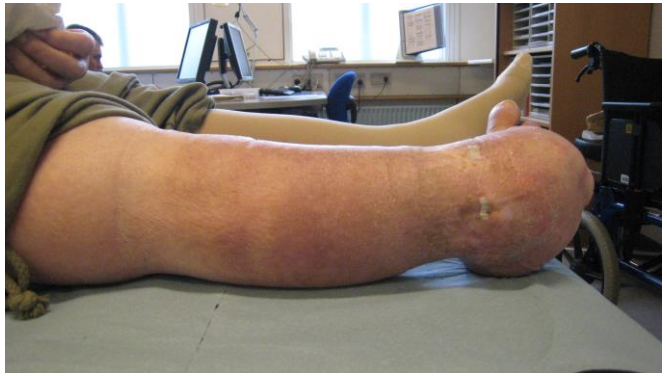

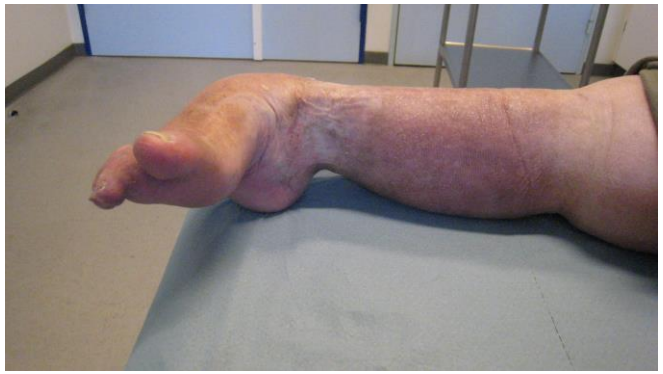

Cerebral parese

Sequelle PEV

Posttraumatisk

Symptomgivende platfod fejstilling

Apopleksi sequelle

Charcot-Marie-Tooth

Deform

Ustabilt

Smertefuld

- **D**eform
- **U**stabilt
- **S**merteful

predispositioner

- Medfødt fejstillniger : PEV, tarsal coalitio, pes plano-valgus
- Neurogen : polio eller sensorik og motorik medfødt neuropathy (CMT)
- RA
- Trauma
- Erhvervet platfod

diagnostik

- Anamnese (især smerter anamnese)
- Objektiv undersøgelse
- Billeder diagnostik:

  Rtg (AP+lateral stående, Saltzman/lang film og Broden subtalar)

  CT

  PED CT

  MRI (sene patologi, RA, PVNS pigmented villonodular synovitis, fibrous coalitio, osteonekrosis)

  knogler scintigraphi (sensitive but lacks specificity)

  UL scaning (sene og ligament patologi)
- Diagnostisk intra-articular injektioner
- Gait analyse

Bagfods stilling

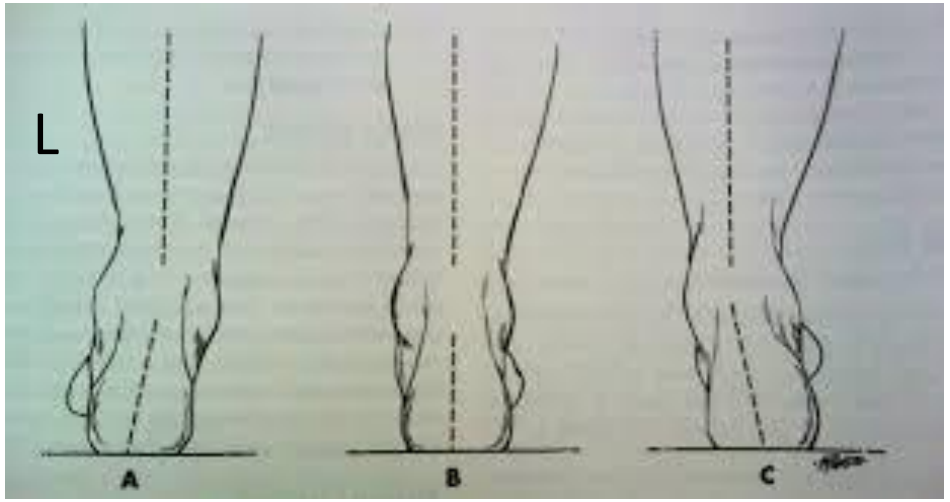

L
R
a
b
A
H
L
R

Start..
PACS WFM
2D - 0401651764\ - 04-07-2016
hel3
13:40
Filer
Redigér
Visning
Værktøjer
Hjælp
3D
VX
FUS
DOC
SR
WFM
04-07-2016
DXT
STÅENDE
DXT
DXT

ID: 6803284509
a
A
b
A
R
L
P
c
H
P
A
F
d
H
R
L
F

a

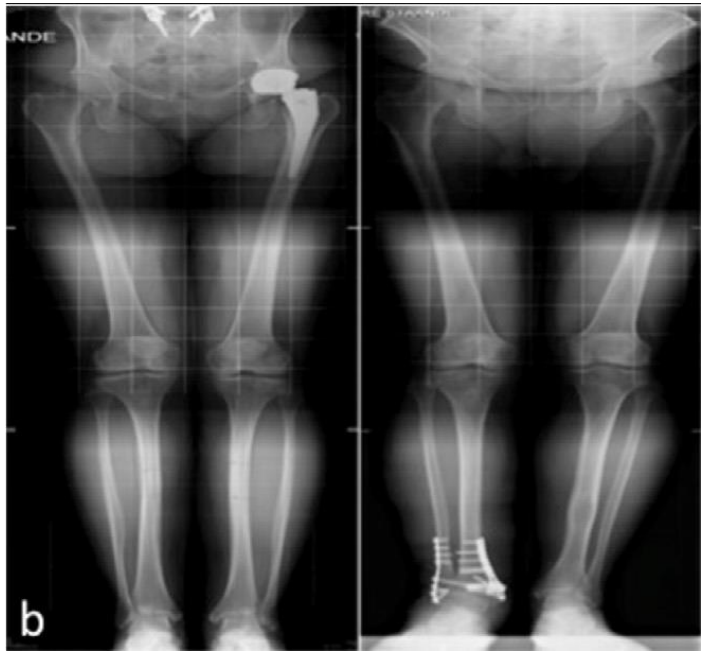
b

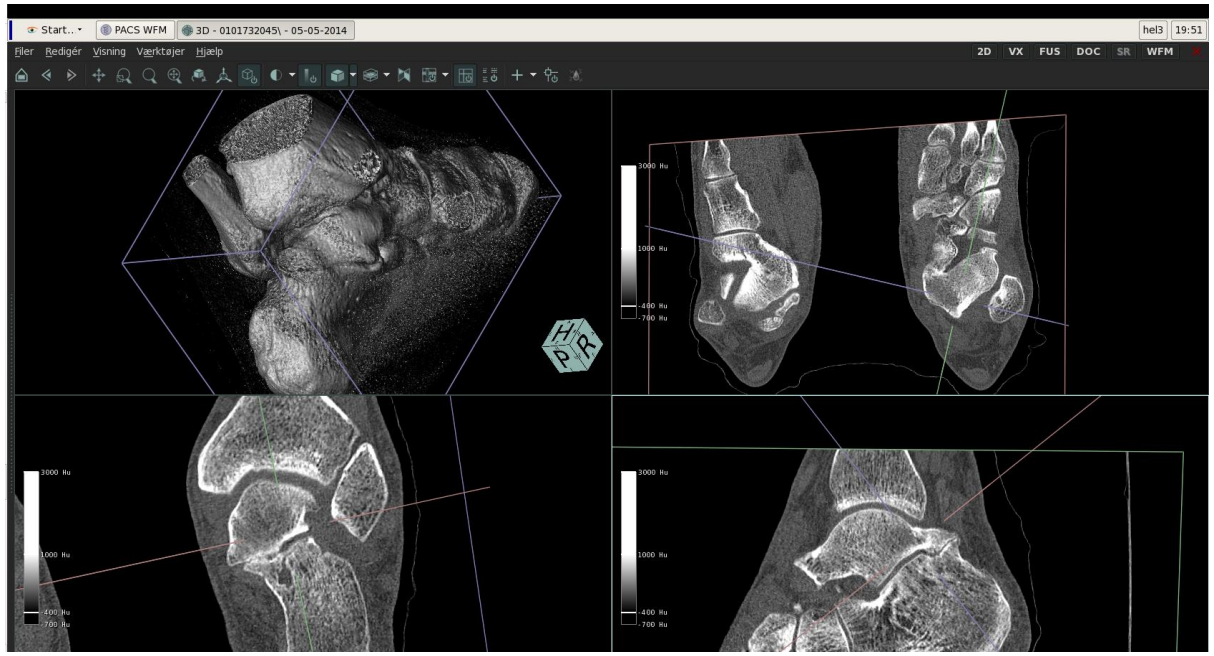
Start..
PACS WFM
3D - 0101732045\ - 05-05-2014
hel3
19:51
Filer Redigér Visning Værktøjer Hjælp
2D VX FUS DOC SR WFM
3000 Hu
1000 Hu
-400 Hu
-700 Hu

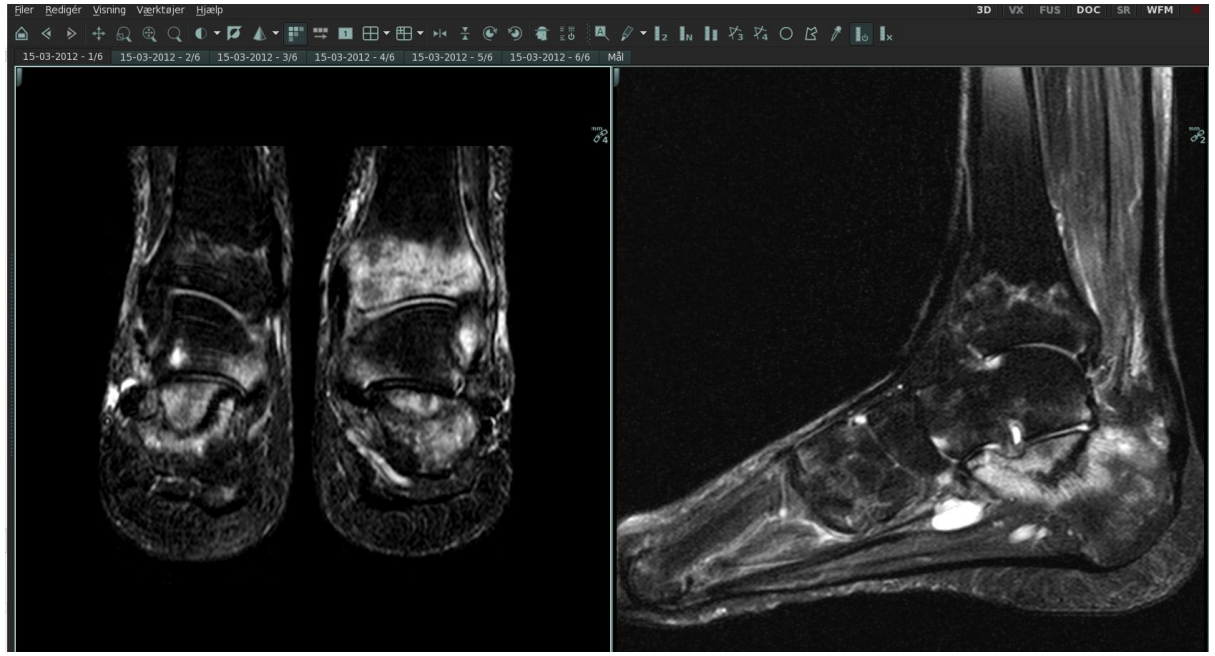
Filer Redigér Visning Værktøjer Hjælp
3D VX FUS DOC SR WFM
15-03-2012 - 1/6
15-03-2012 - 2/6
15-03-2012 - 3/6
15-03-2012 - 4/6
15-03-2012 - 5/6
15-03-2012 - 6/6
Mål

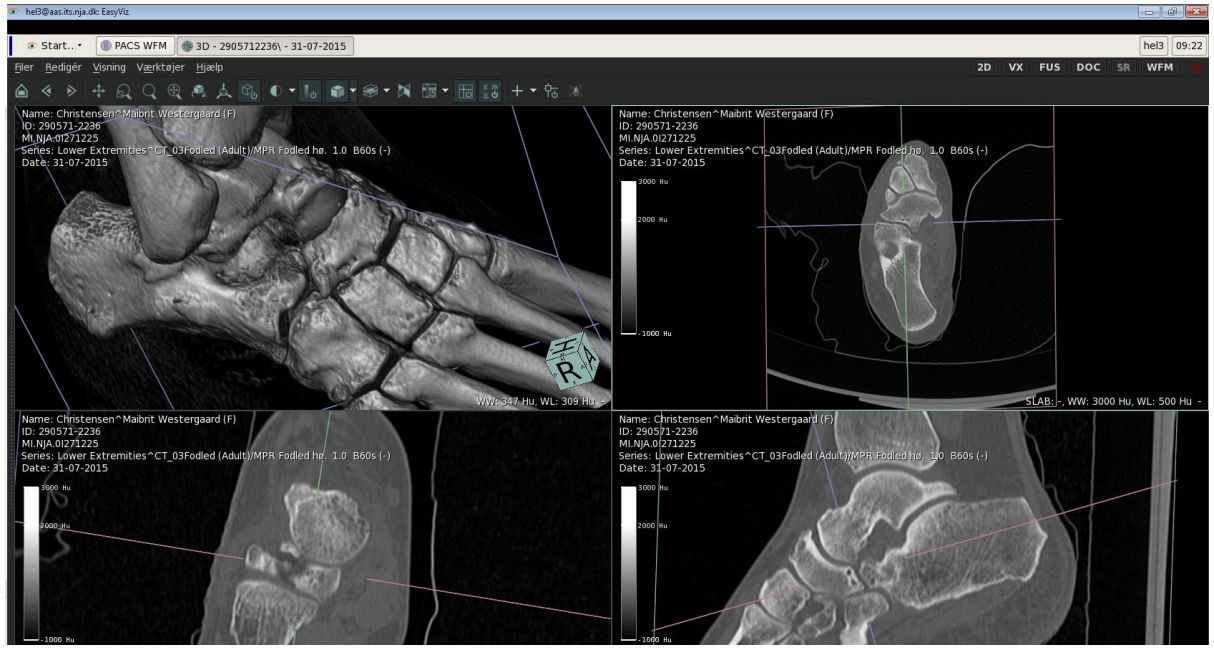
hel3@aas.its.nja.dk: EasyViz
Start..
PACS WFM
3D - 2905712236\ - 31-07-2015
hel3
09:22
Filer Redigér Visning Værktøjer Hjælp
2D VX FUS DOC SR WFM
Name: Christensen^Maibrit Westergaard (F)
ID: 290571-2236
MI.NJA.0I271225
Series: Lower Extremities^CT_03Fodled (Adult)/MPR Fodled hø. 1.0 B60s (-)
Date: 31-07-2015
WW: 347 Hu, WL: 309 Hu
SLAB: -, WW: 3000 Hu, WL: 500 Hu
3000 Hu
2000 Hu
-1000 Hu

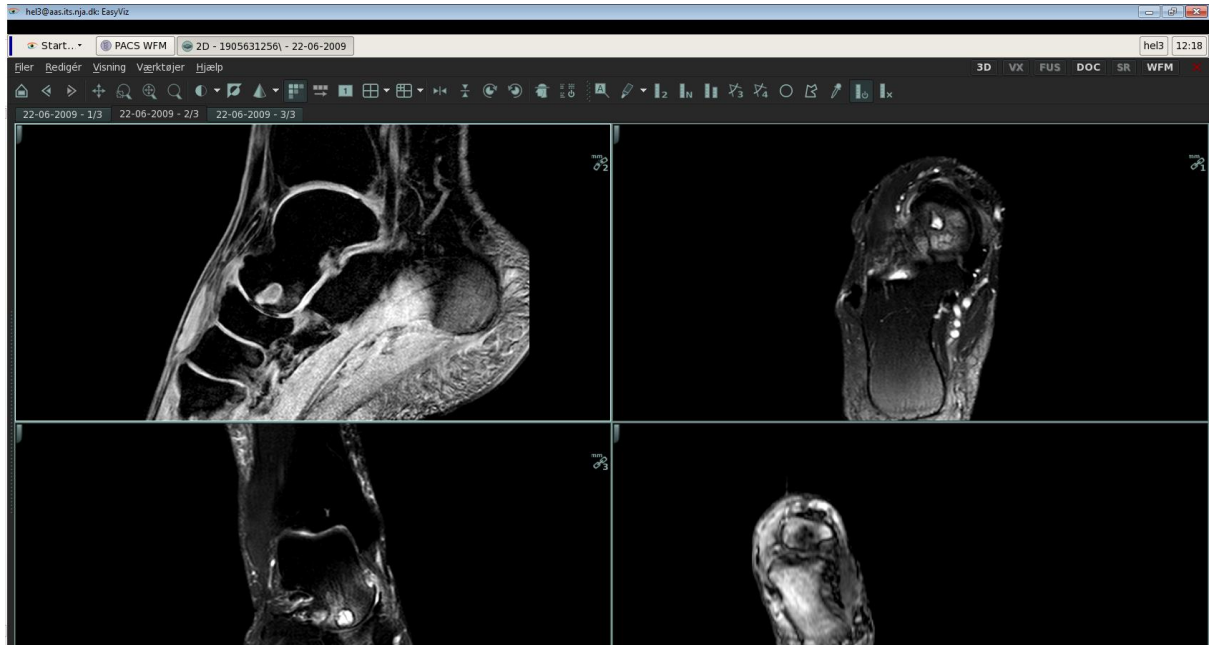
hel3@aas.its.nja.dk: EasyViz
Start..
PACS WFM
2D - 1905631256\ - 22-06-2009
hel3
12:18
Filer Redigér Visning Værktøjer Hjælp
3D VX FUS DOC SR WFM
22-06-2009 - 1/3
22-06-2009 - 2/3
22-06-2009 - 3/3

Behandling:

Konservative:

- Vægt reduktion ved højt BMI
- Tilpasning af aktiviteter
- Steroid injektioner/NSAID
- Fysioterapi
- Stiv gængesål
- Indlæg
- Stock/krykker
- Fodkapsel

Kirurgisk:

- Ostetomier
- artrodeser

Konservativ behandling

- Vægt reduktion ved højt BMI
- Tilpasning af aktiviteter
- Steroid injektioner/NSAID
- Fysioterapi
- Stiv gængesål
- Indlæg
- Stock/krykker
- Fodkapsel

kirurgi

Åbent

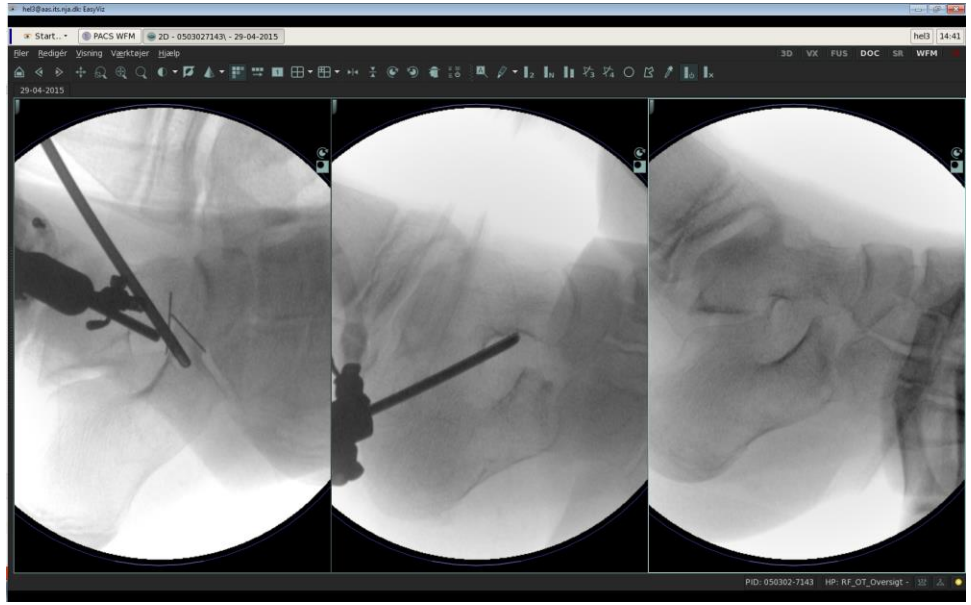

Skopisk

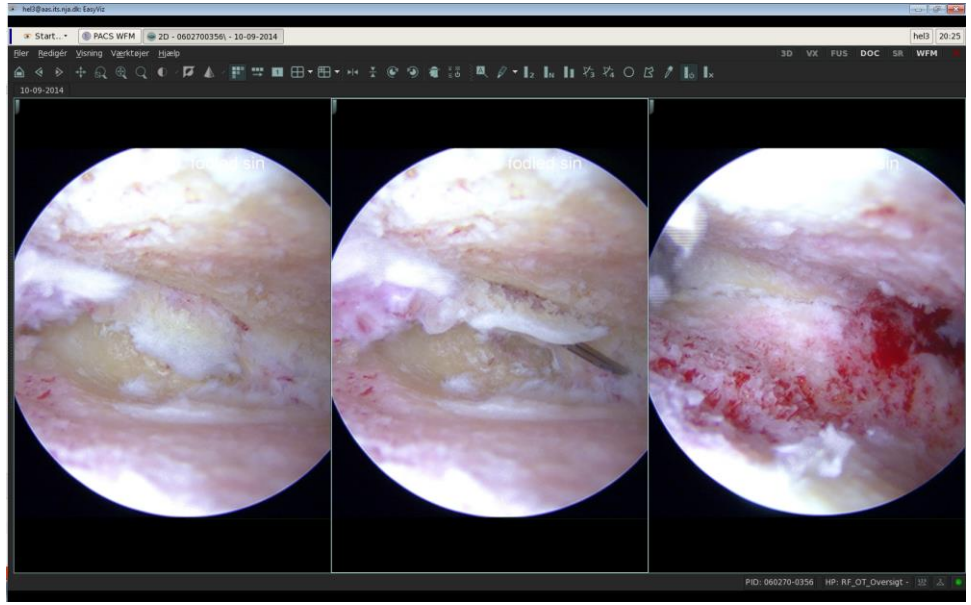

Foot and Ankle Surgery 21 (2015) 97–102

Contents lists available at ScienceDirect

Foot and Ankle Surgery

journal homepage: www.elsevier.com/locate/fas

Arthroscopic triple and modified double hindfoot arthrodesis

N.A. Jagodzinski *, A.M.J. Parsons, S.W. Parsons

The Royal Cornwall Hospital, Truro, United Kingdom

ARTICLE INFO

Article history:
Received 18 April 2014
Received in revised form 11 October 2014
Accepted 17 October 2014

Keywords:
Arthroscopic
Arthrodesis
Fusion
Hind foot
Subtalar
Double
Triple

ABSTRACT

Background: Arthroscopic arthrodesis is an accepted technique for the ankle but less commonly reported for multiple hindfoot joints. We present a case series review to establish the feasibility of this surgery.
Methods: In a consecutive series of 112 arthroscopic hindfoot arthrodeses, 18 involved decortication and fusion of 2 or 3 hindfoot joints. These were reviewed to identify complications, union rates and improvement over preoperative state.
Results: Mean age was 62 (45–78). Mean follow-up was 4.4 (1.75–7.5) years. There were no perioperative complications. The four patients with triple fusions united with good or excellent outcomes. Of 14 patients with subtalar and talonavicular arthrodeses there were three talonavicular non-unions.
Conclusions: Arthroscopic double and triple arthrodeses appear feasible salvage options for pain and deformity. Decortication of all three joints and rotatory correction of deformity is possible whilst preserving the soft tissue envelope. Late adjacent joint pain and arthrosis can occur.
© 2014 European Foot and Ankle Society. Published by Elsevier Ltd. All rights reserved.

Foot and Ankle Surgery 23 (2017) 9–15

Contents lists available at ScienceDirect

Foot and Ankle Surgery

journal homepage: www.elsevier.com/locate/fas

Subtalar arthroscopic arthrodesis: Technique and outcomes

Jesús Vilá-Rico [a,b,*], María Angeles Mellado-Romero [a], Beatriz Bravo-Giménez [a], Verónica Jiménez-Díaz [a], Cristina Ojeda-Thies [a]

[a] Hospital Universitario Doce de Octubre, Madrid, Spain
[b] Department of Surgery, Universidad Complutense, Madrid, Spain

ARTICLE INFO

Article history:
Received 20 May 2015
Received in revised form 16 November 2015
Accepted 26 November 2015

Keywords:
Subtalar arthroscopic arthrodesis
Hindfoot artrhroscopy

ABSTRACT

Purpose: The goal of this study was to describe the surgical technique and our results with arthroscopic posterior subtalar arthrodesis.

Material and Methods: Retrospective case series of 65 patients (38 men and 27 women) averaging 50 years of age (range 21–72 years) undergoing posterior arthroscopic subtalar arthrodesis using one or two percutaneous 6.5–7.3 mm screws between May 2004 and February 2011, with a mean follow-up of 57.5 months (range 24–105 months).

Results: We achieved a 95.4% union rate after an average of 12.1 weeks (range 9 to 16 weeks). 12.3% of patients suffered complications, including superficial infection, nonunion and need for hardware removal. The AOFAS score improved from 51.5 points (19–61 points) preoperatively to 81.9 points (60–94 points) in the postoperative period.

Conclusions: We describe the surgical technique for arthroscopic subtalar arthrodesis, which as proven to be a safe and reliable technique in our experience, with consistent improvements in AOFAS scores.

© 2015 European Foot and Ankle Society. Published by Elsevier Ltd. All rights reserved.

mål

Smertefri, plantigrade, stabile fod

komplikationer

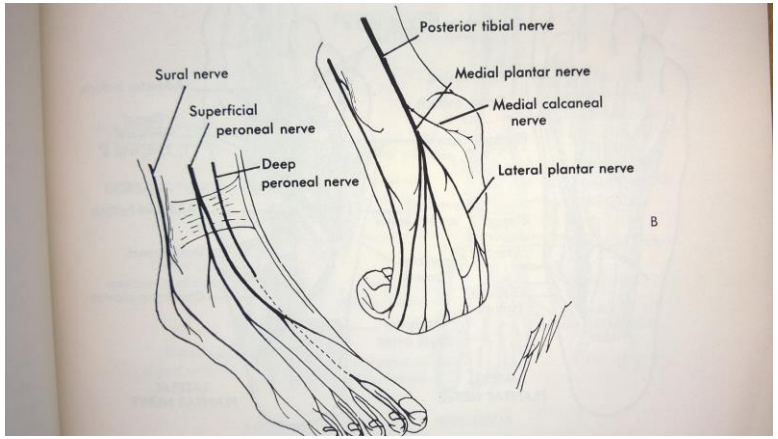

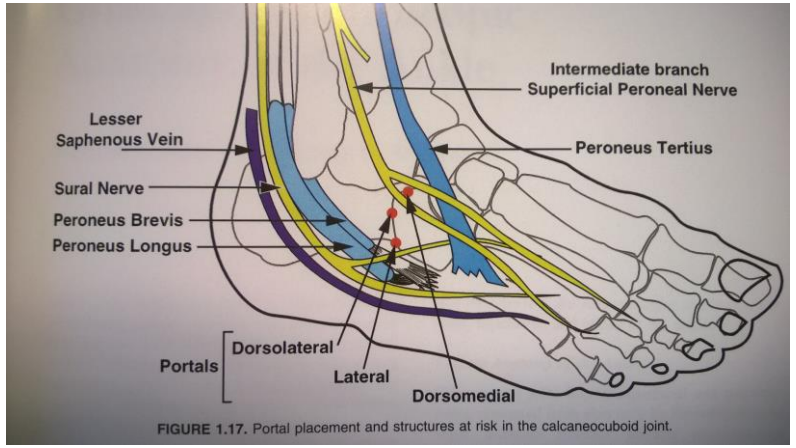

FIGURE 1.17. Portal placement and structures at risk in the calcaneocuboid joint.

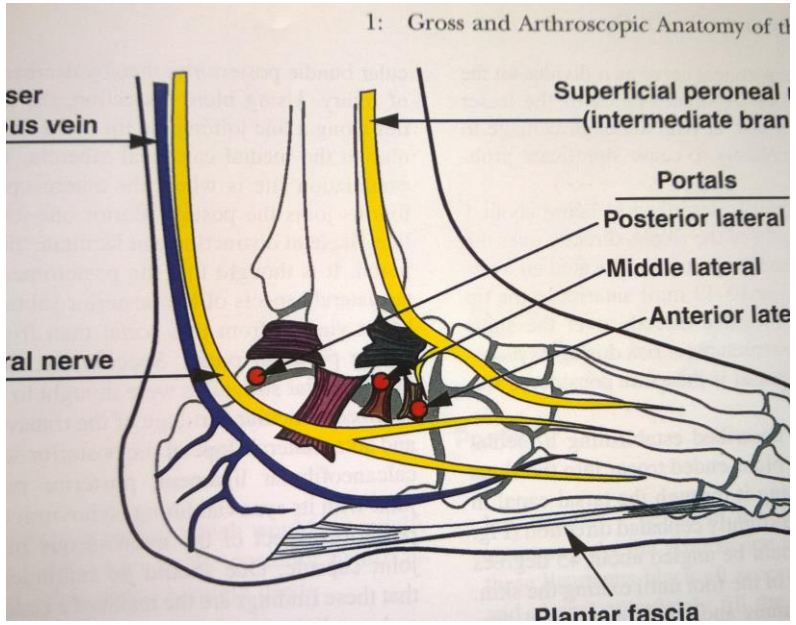

- Sår helings problemer
- Forsinket knogler heling
- DVT
- Pseudoartrose (4,5%-23%)
- Nerve skade 7% (n.peronues, n.suralis, n.TP)
- Kroniske neurogene smerter inkl.CRPS
- Sene skader, tendinitis
- Artrose i nabo led (talo-crural eller midfod)
- Malaligment (typisk VARUS)

Posterior skopi portals

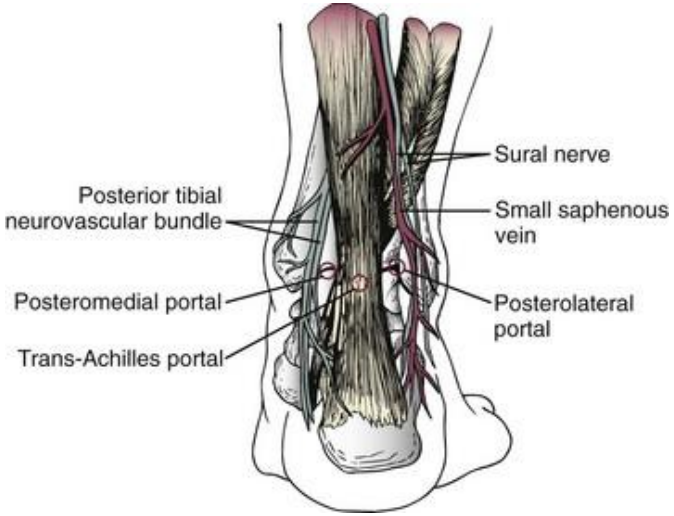

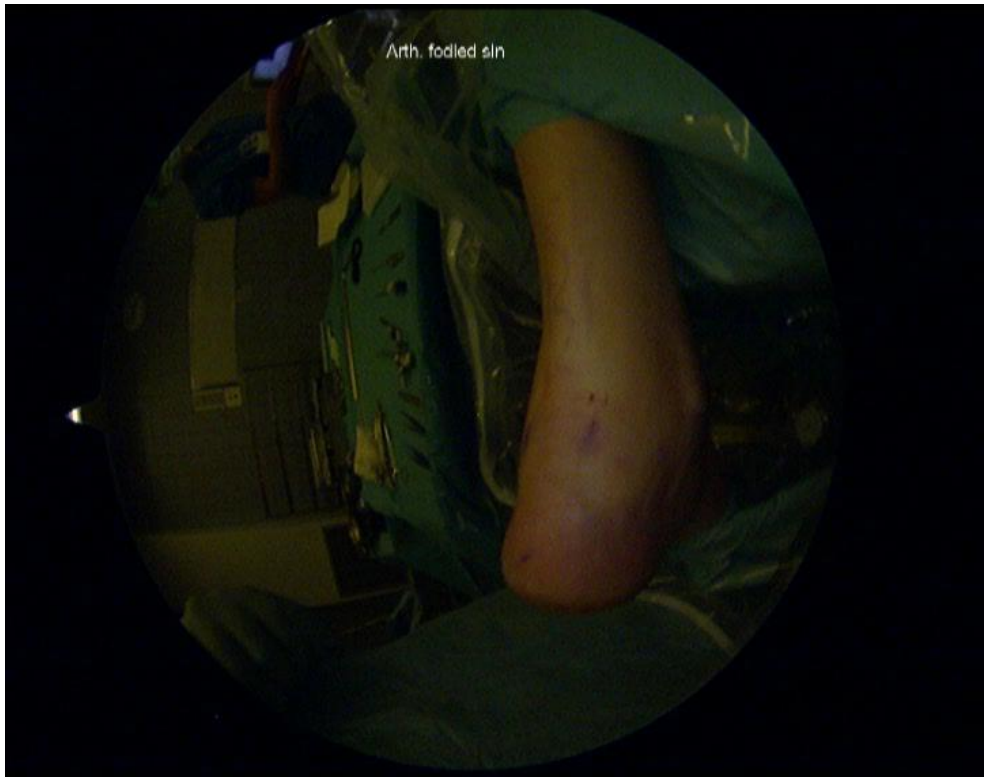

Posterior skopi

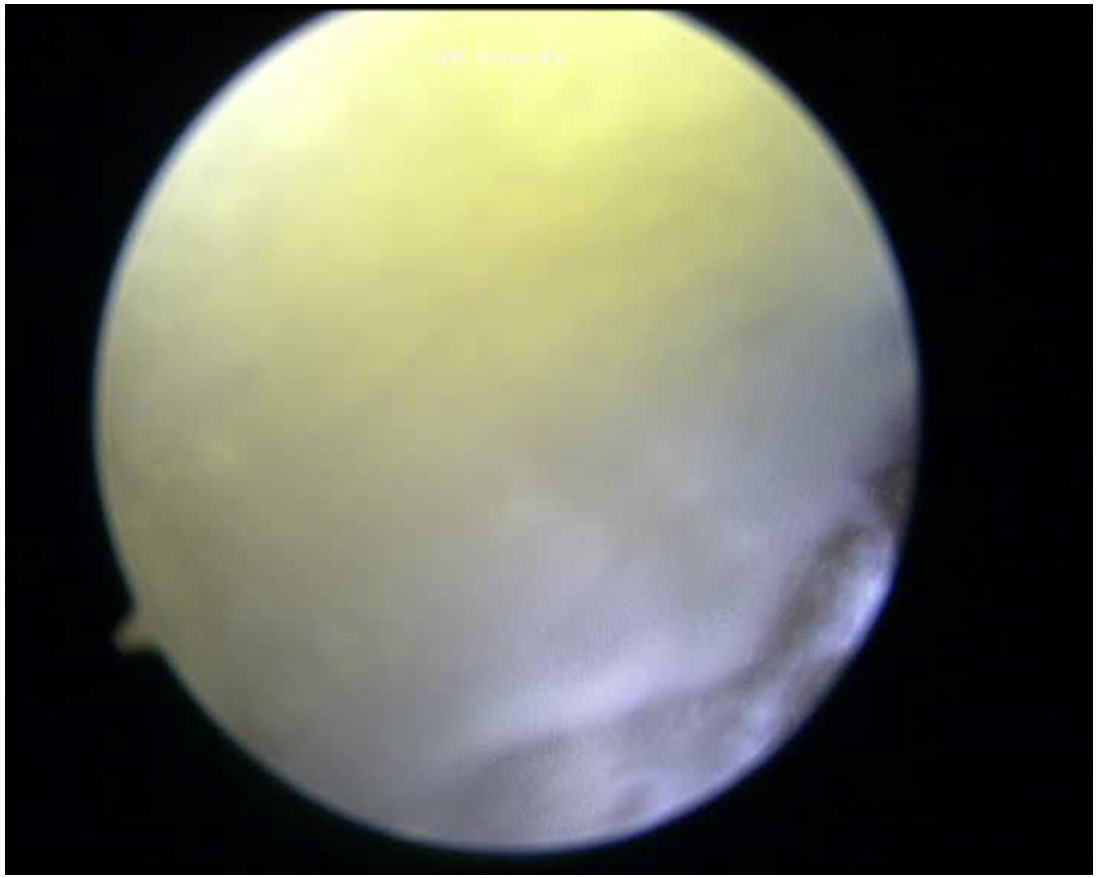

Indikationer for bagfodsdese

- Rigid bagfodsfejlstilling f.e. PEV, CMT, pes planus,
- Posttraumatisk artrose
- Symptomgivende coalito
- Symptomgivende RA indiceret artrose
- Fod deformiteter efter Charcot artropati

tripleartrodesis

Ryerson beskrevet i 1923

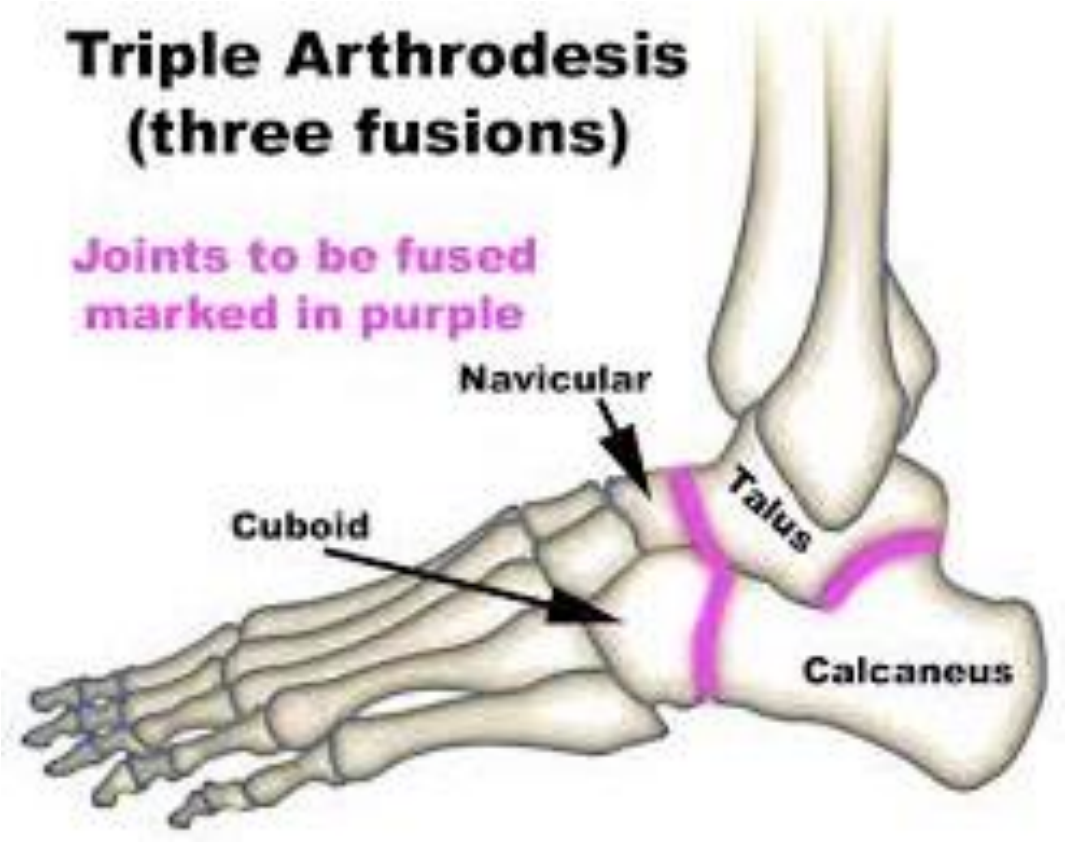

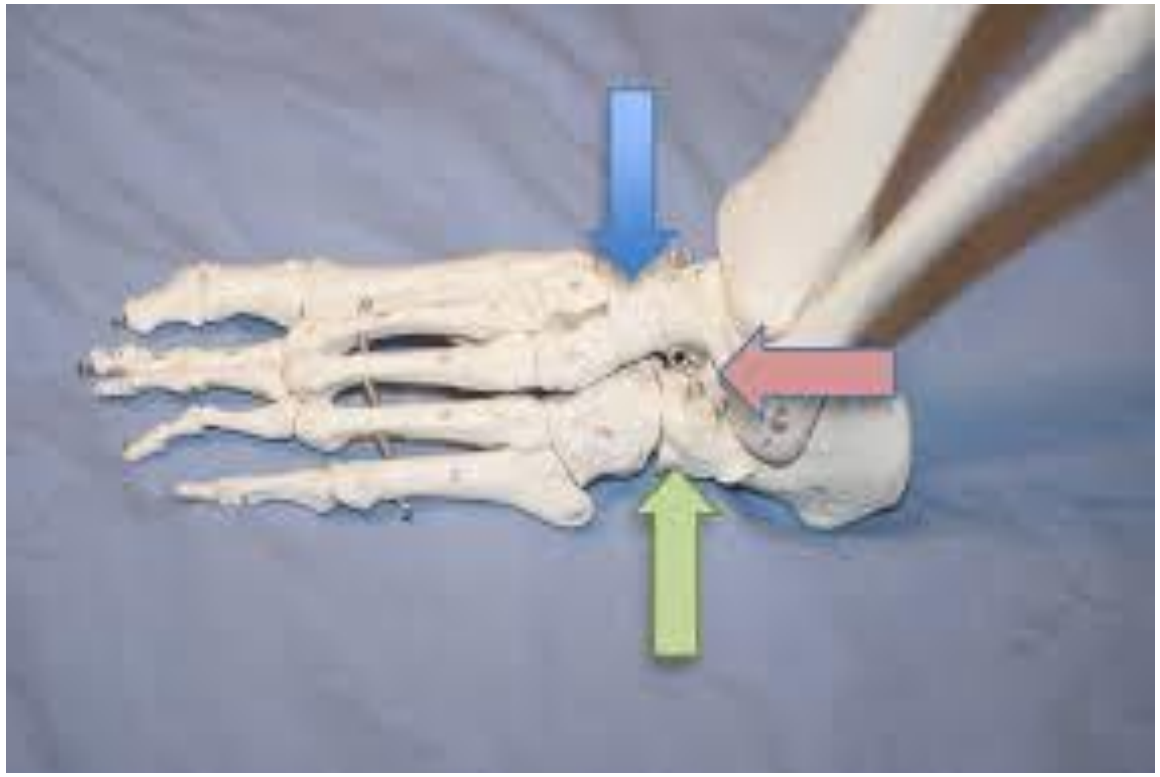

Charcot-Marie-Tooth

Tiltagende fejstilling af begge fødder gennem mange år.

Fejstillinger ligner morfars fødder.

Moderate smerter. Gang besvær.

Klinisk stiv bagfødder uden manuel korrektion.

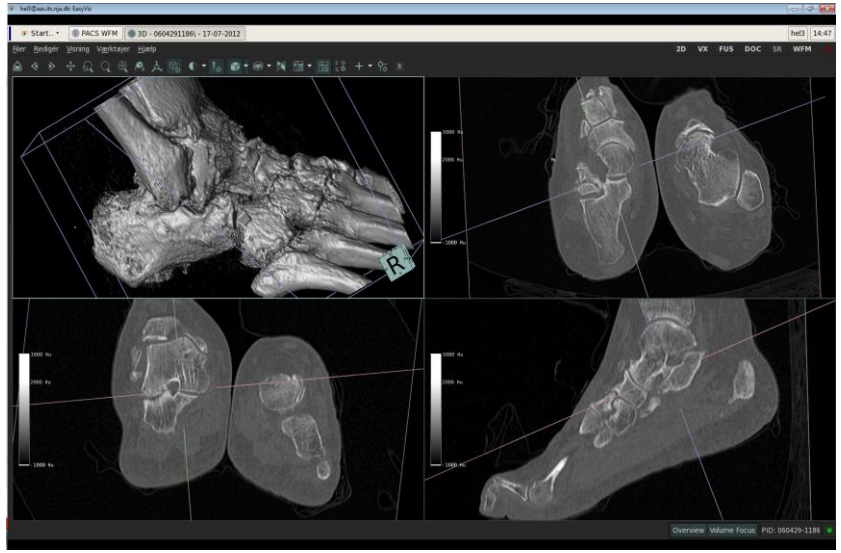

83 årig kvinde med tiltagende belastnigs relaterende smerter i helle bagfoden.
Klinisk bagfod stå i udtalt valgus stilling og har kun smerterfuld, rokke bevægelse tilbage.

62 årig kvinde med tiltagende platfod, klager over belastning relaterende smerter under medial malleol. Konservativ tilgang med indlæg haft kun kortvarig virkning

2008

64 årig mænd, for 10 år siden bilateral calcaneus fraktur efter fald fra en stige. Efter ORIF kom tilabge på arbejde som maler, men i sidste et par år tiltagende smerter fra hø. hæl region.

2016

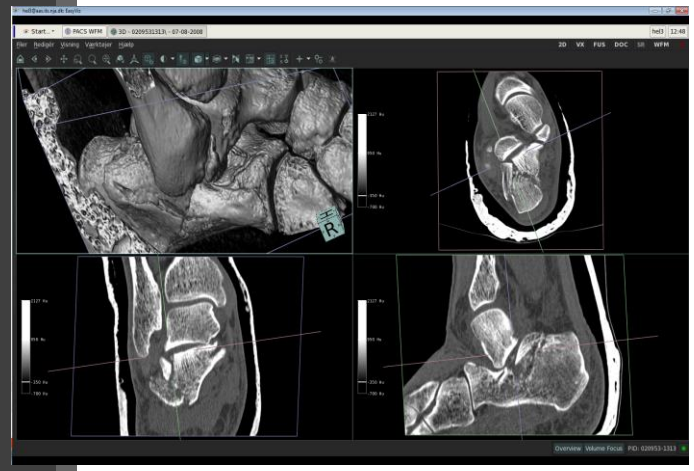

70 mænd henvist af e.l. pga. ankel smerter, som forværres med gang på ujævn taraen.

Klinisk findes neutral stillet bagfod, måske anelse i varus, hævelse ved antero-medial ankel, men lidt mere distalt. Talo-crural normal og smertefri ROM. Supination og pronation af forfoden fremkalde smerter. Desuden kendt med psoriasis gigt.

Double arthrodesis: talo-navikular + subtalar

Hook beskrevet i 1921

Seropositive Reumatoid Artrit

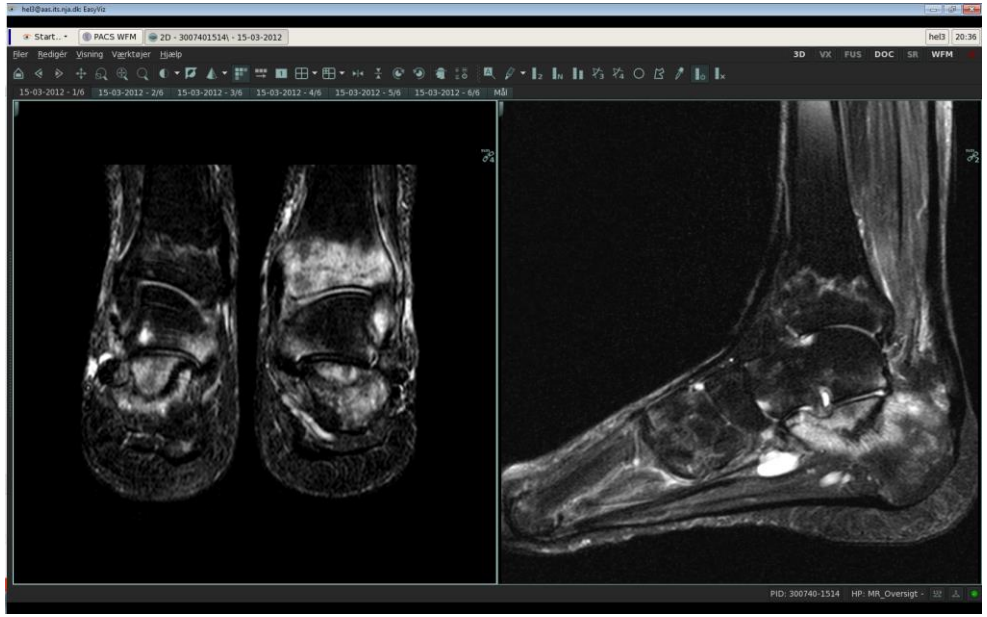

47 kvinde, tidligere håndboldspiller, talrige ve. ankel distorsioner. Nu tiltagende belastning relaterede smerter, især ved gang på ujævn taraen.

Er under udredning for IBS fordi har også andre symptomer fra bevæge apparat.

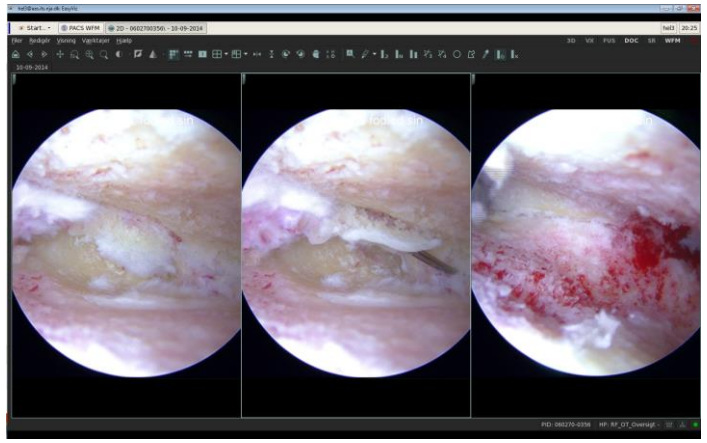

44 mænd har hele sit liv døjet med smerter fra ve. bagfod, som barn kunne ikke løbe og ve. fod føltes altid usikkert.

Klinisk findes ve. bagfod stillet i varus, uden varisering med tå stand. Bagfod føles fuldstændig stiv.

Pt. var utrolig glad efter 6 ugers gips immobilisering, fordi første gang i sit liv var smertefri.

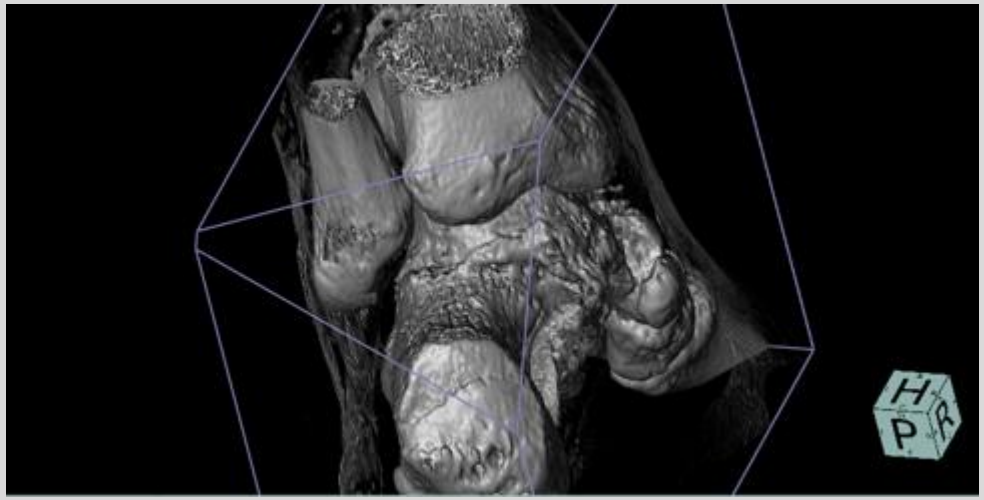

Removal of coalitio

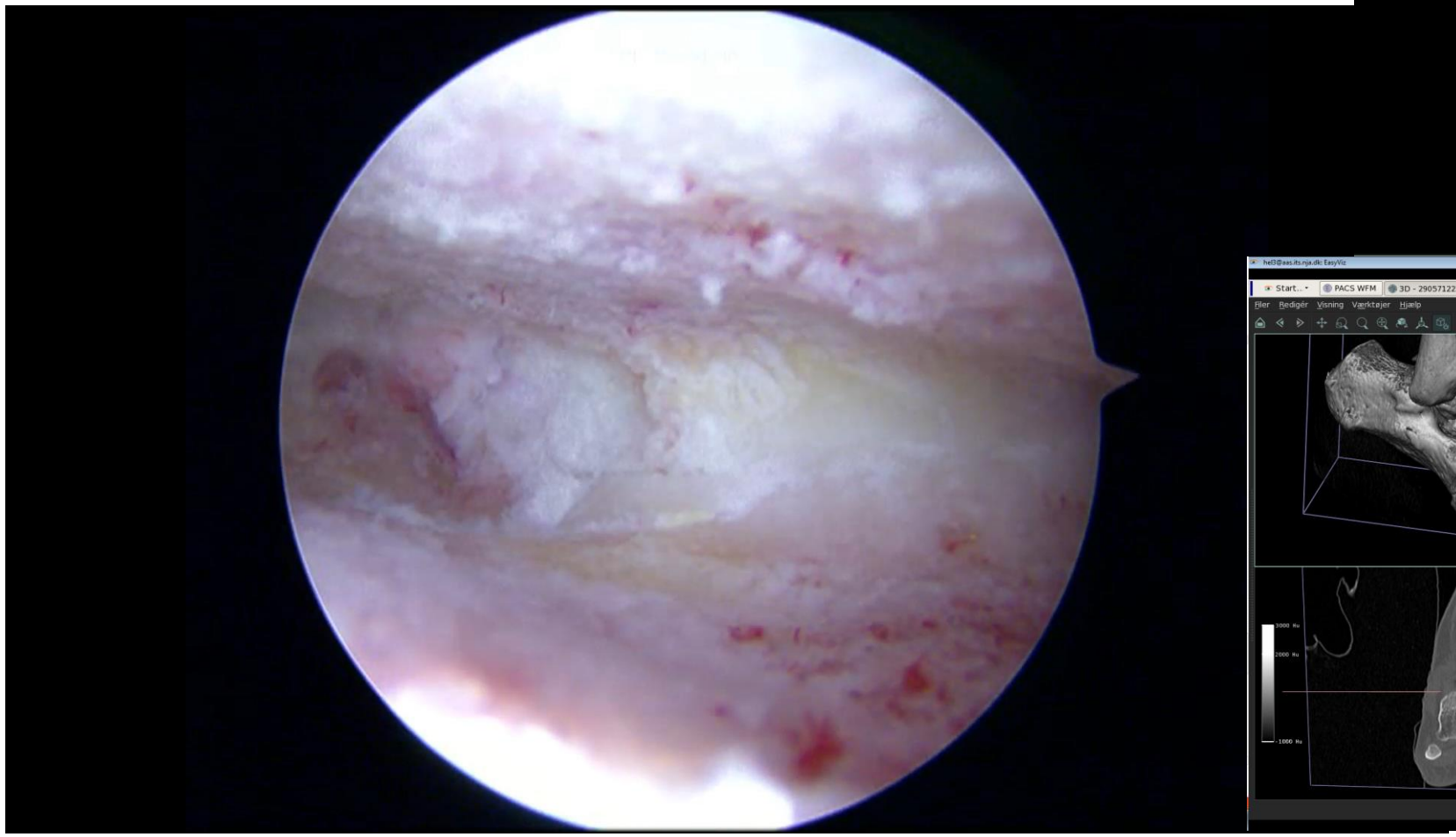

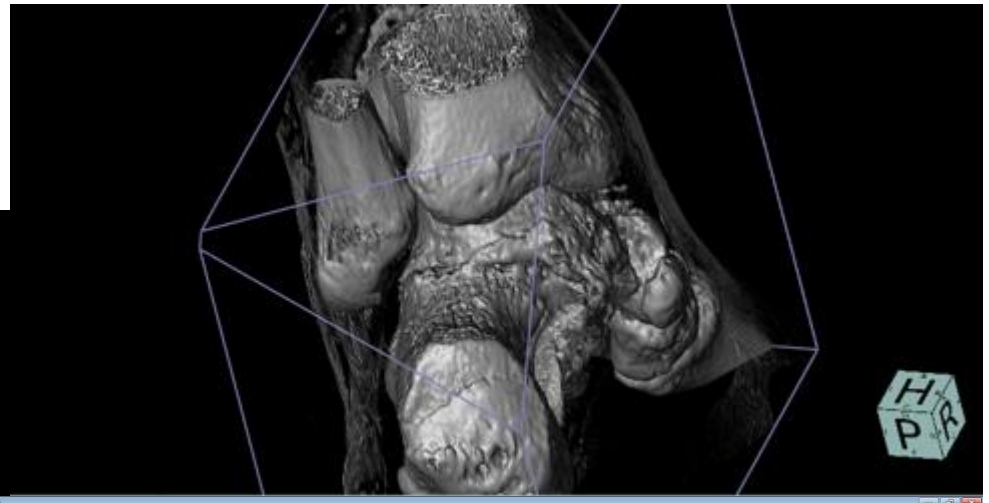

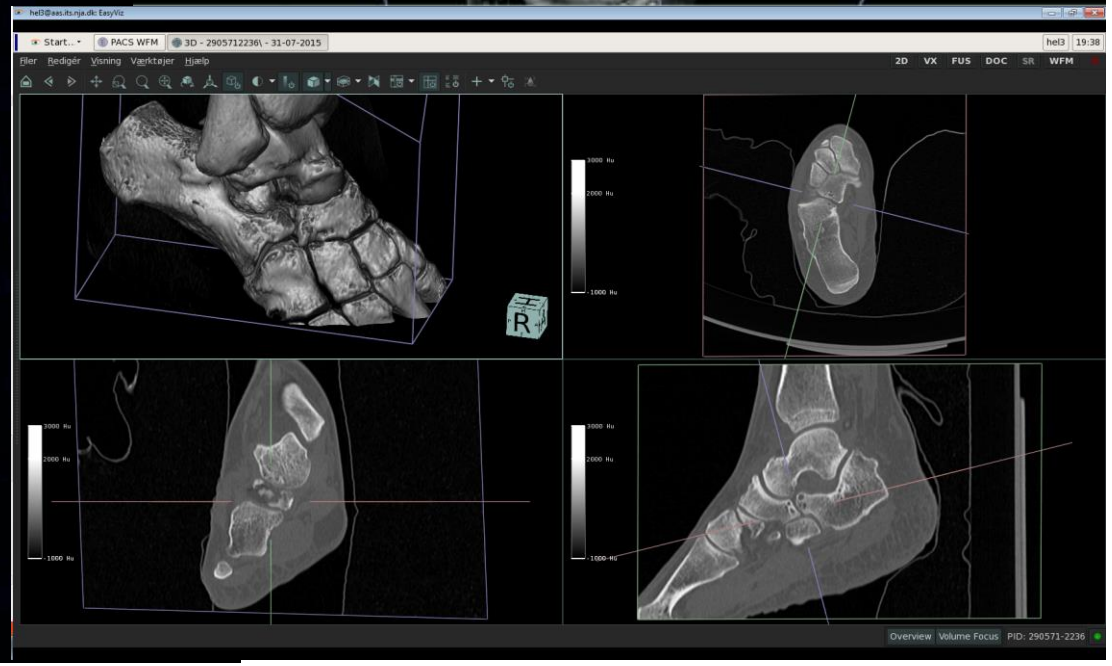

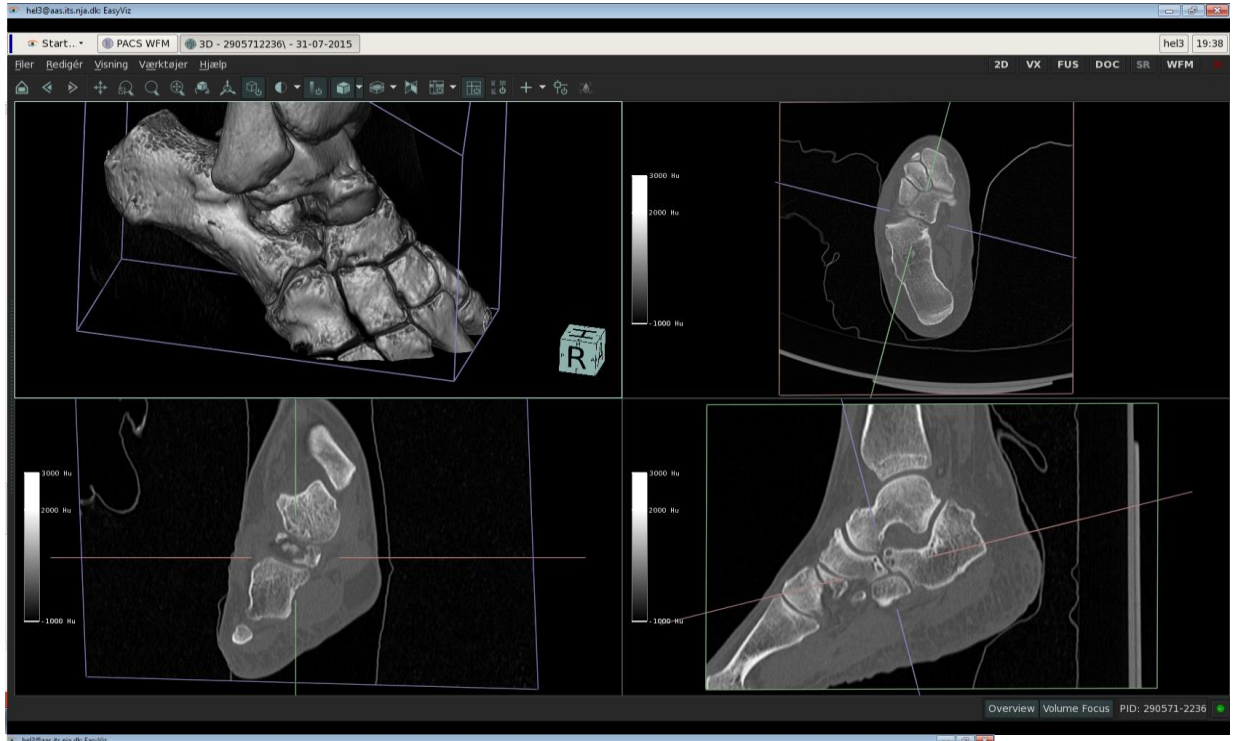

Calcaneo-navikular coalitio

46 mænd kendt med bipolar depressive disorder, klager over smerter i begge fødder siden barndom, derfor har aldrig deltaget i idræt. Søskende har også ”skæv” fødder.

Kliniks findes begge hæl i varus, højt svang og hårdt udbygning ved sinus tarsi.

Mange årige type 2 diabetiker, kendt med alle sent komplikationer inkl.neuropati. I sidste 18 mdr har været i behandling for rosen via e.l. Har ingen smerter, men ankel hæver meget op, er hverken varmt eller rødt længere.

Post op protokol

- Gips i 12 uger
- Minus vægt i 6 uger
- Gradvis stigning af belastning
- Rtg kontrol efter 12 uger
- GOP
- 6 mdr kontrol mhp indlæg/sko

PROMS (Patient Reported Outcome Measures)

Button har beskrevet 49 forskelige: bl.a.

- AOFAS (American Orthopedic Foot and Ankle Score)
- VAS (Visual Analog Scale)
- FFI (Foot Function Index)
- FAOS (Foot and Ankle Outcome Score)
- MOXFQ (Manchester-Oxford Foot Questionnaire)
- SEFAS (Self-reported Foot and Ankle Score)
- SF 36
- EFAS

QUESTIONS

No.	Question	Answer				
1 N/A ◯	Do you have pain in your foot and/or ankle when you are at rest?	Always 0	1	2	3	Never 4
2 N/A ◯	How far can you walk before you get pain in your foot and/or ankle	Impossible 0	1	2	3	No limitation 4
3 N/A ◯	How much has your gait (i.e., the way you walk) changed because of your foot and/or ankle problem?	Extreme gait change 0	1	2	3	No change 4
4 N/A ◯	Do you have difficulty walking on uneven surfaces?	Always 0	1	2	3	Never 4
5 N/A ◯	Do you have pain in your foot and/or ankle when you are walking?	Always 0	1	2	3	Never 4
6 N/A ◯	How often do you have pain in your foot and/or ankle during physical activity?	Always 0	1	2	3	Never 4

Ortopædkirurgi, Hjørring

De ortopædkirurgiske afsnit behandler dig, hvis du har problemer med eller er kommet til skade med knogler eller led.

FIND AFSNIT

I Ortopædkirurgi Hjørring har vi følgende afsnit:

Bemærk at linkene nedenfor åbner på Aalborg Universitetshospitals hjemmeside

- Sengeafsnit 109 for Ortopædkirurgi, Hjørring
- Dagafsnit for Ortopædkirurgi, Hjørring
- orium for kirurgi
- Center for Artroskopi
- Operationsafsnit for Ortopædkirurgi, Hjørring
- Sårambulatorium for Ortopædkirurgi, Hjørring

Giv os din feedback

KONTAKT

Ortopædkirurgisk Afdeling, Hjørring

Tlf.:
97 64 16 16

Mail:
ortohjoerring@rn.dk

Regionshospital Nordjylland, Hjørring
Bispensgade 37
9800 Hjørring

Undersøgelser og behandlinger

Se vores pjecer om de undersøgelser og behandlinger, vi foretager i Ortopædkirurgi Hjørring.

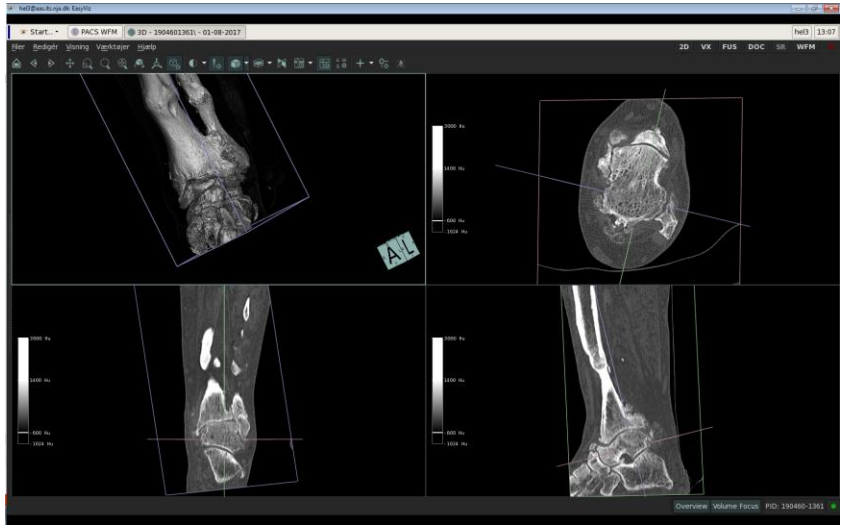

For 30 år siden, involveret i MC ullyke, konservativ behandlet åben crus fraktur. Nu oplever forværing af smerter.

Pes planus

Start...
PACS WFM
17-05-2017
3D
VX
FUS
DOC
SR
WFM
PID: 120464-1583
HP: CR/DX Knogle generel uden priors

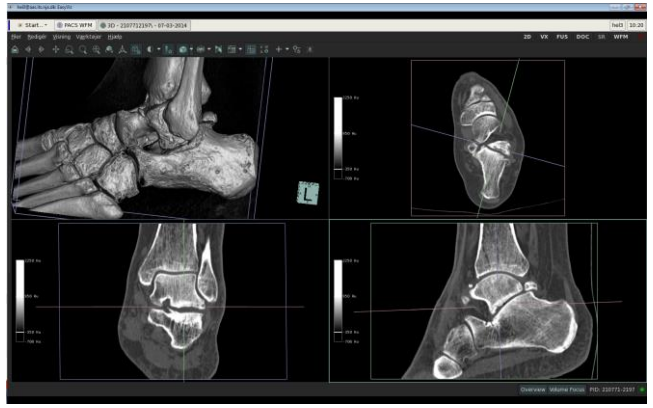

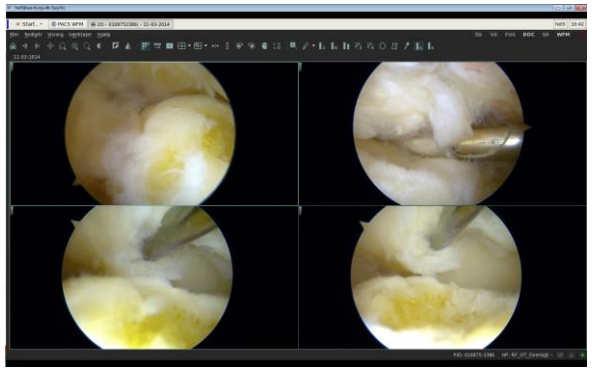

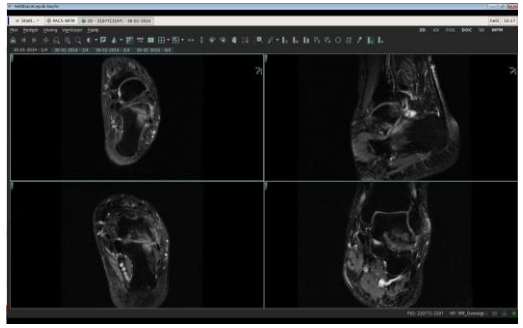

45 årig mænd som var udsat for vrid traume af ve. fod på arbejde, klager over belastning relaterende smerter i hælen og omkring Achillessenen, kan ikke går normalt især på ujævnt taraen, halte, bagfoden hæve op sidst på dagen