PLANTAR FASCIITIS IN THE ATHLETE

FROM PATHOMECHANICS TO SURGERY

Manuel Monteagudo

Orthopaedic Foot Ankle Surgery
Orthopaedic&Trauma Deparment
Hospital Universitario Quirónsalud Madrid
Fac Medicine UEM Madrid, Spain
mmontyr@yahoo.com

monteaceira

Danish Foot and Ankle Society
DFAS
Dansk Fod- og Ankelkirurgisk Selskab



Universidad Europea de Madrid
Laureate International Universities

quirónsalud
La salud persona a persona

Hospital Universitario quirónsalud
Madrid

Universidad Europea de Madrid

Laureate International Universities

CONSERVATIVE TREATMENT: Eccentric loading

Journal of Biomechanics 42 (2009) 2702–2707

Contents lists available at ScienceDirect

Journal of Biomechanics

journal homepage: www.elsevier.com/locate/jbiomech
www.JBiomech.com

Biomechanical characteristics of the eccentric Achilles tendon exercise

Marius Henriksen [a,*], Jens Aaboe [a], Henning Bliddal [a,c], Henning Langberg [b]

[a] Clinical Motor Function Laboratory, The Parker Institute, Frederiksberg Hospital, Denmark
[b] Institute of Sports Medicine, Bispebjerg Hospital, Denmark
[c] Center for Sensory-Motor Interaction, Aalborg University, Denmark

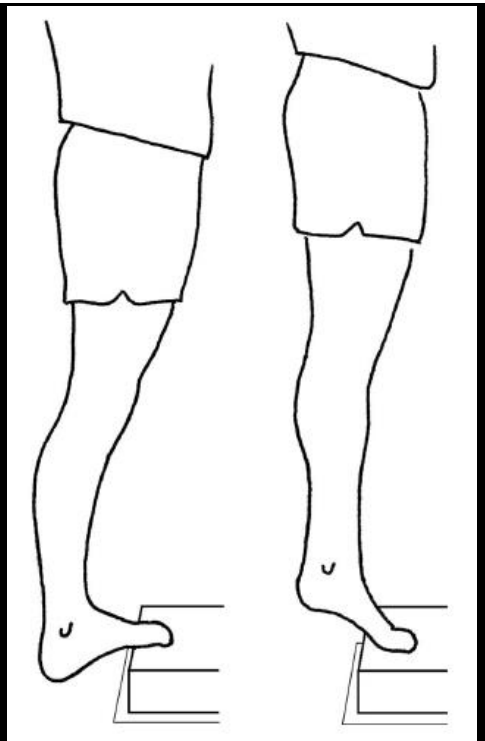

Tobillo-Pie:
Tendinitis
Aquiles

PLANTAR FASCIITIS …

Plantar fasciotomy – irregular results

48 to 90% patient satisfaction

Davies MS, Weiss GA, Saxby TS. Plantar fasciitis: how successful is surgical intervention? *Foot Ankle Int* 1999; 20: 803-807.

A BIT OF HISTORY ...

Arandes & Viladot –
ACP system

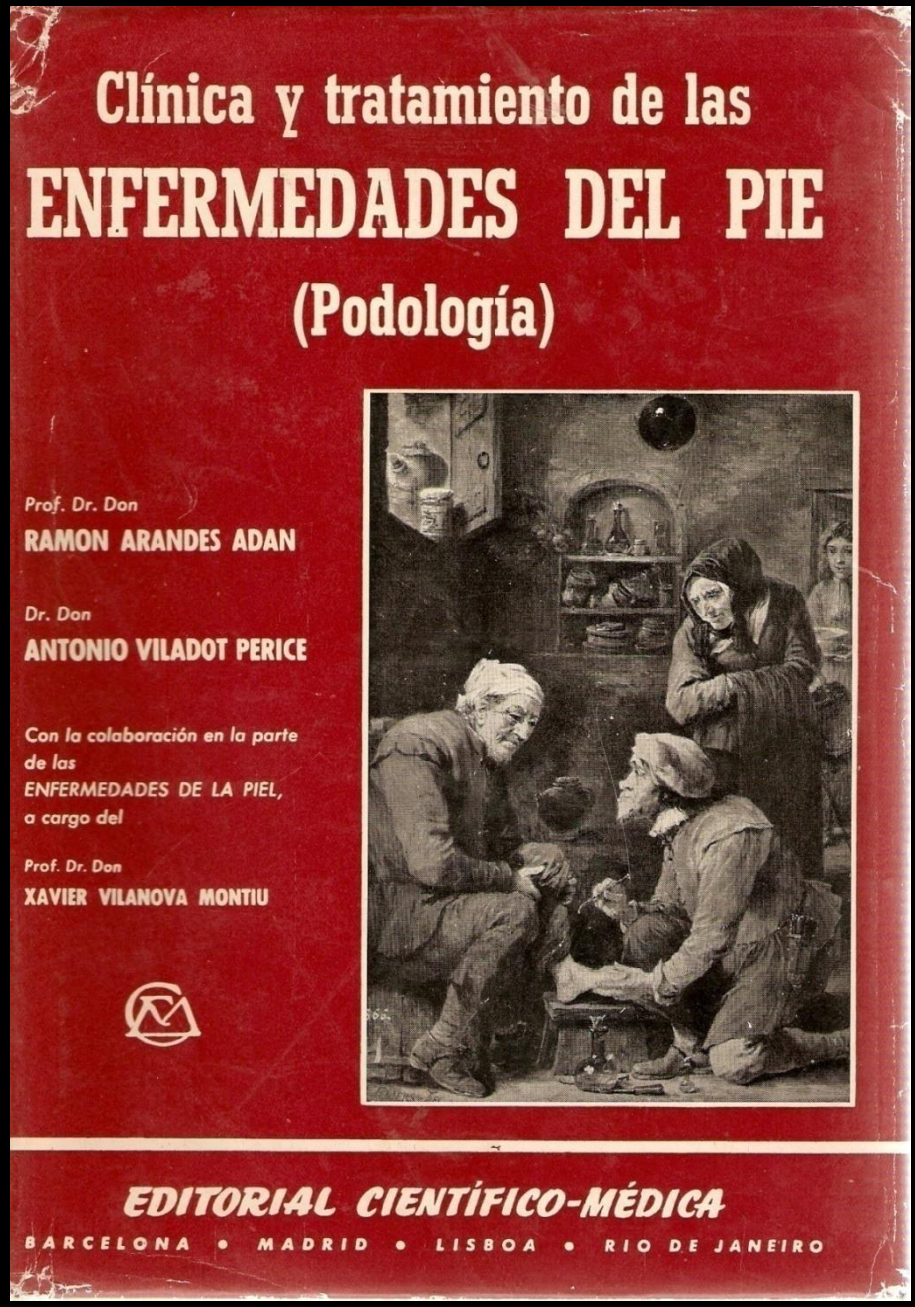

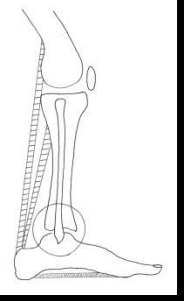

BIOMECHANICAL ASPECTS OF GASTROC-ACHILLES-CALCANEAL-PFASCIA SYSTEM

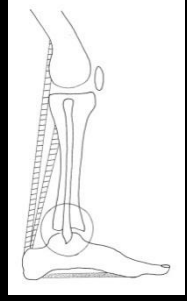

Ankle plantar flexion – knee extension couple

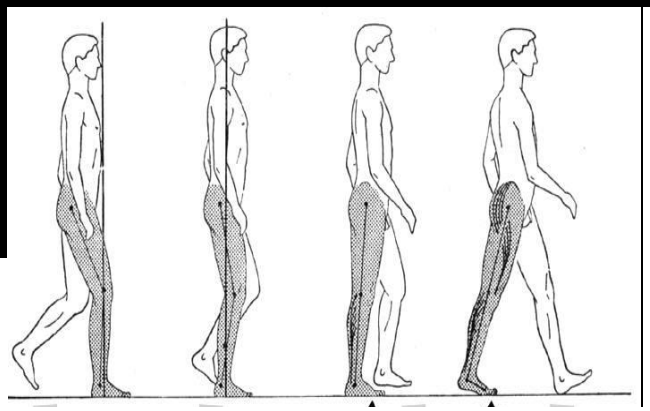

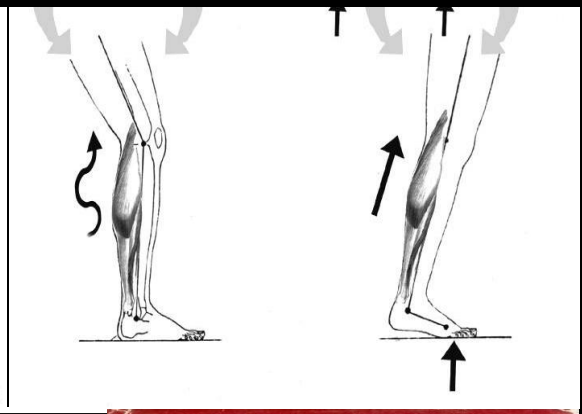

FOOT & ANKLE INTERNATIONAL

The Effect on Ankle Dorsiflexion of Gastrocnemius Recession

Stephen J. Pinney, M.D.; Sigvard T. Hansen Jr., M.D.; Bruce J. Sangeorzan, M.D.
Sacramento, CA and Seattle, WA

FOOT & ANKLE INTERNATIONAL

DOI: 10.3113/FAI.2010.0019

Gastrocnemius Recession to Treat Isolated Foot Pain

John D. Maskill, MD; Donald R. Bohay, MD; John G. Anderson, MD
Grand Rapids, MI

DOI: 10.3113/FAI.2008.0620

Gastrocnemius Recession as Treatment for Refractory Achilles Tendinopathy: A Case Report

Christopher E. Gentchos, MD; Donald R. Bohay, MD; John G. Anderson, MD
Grand Rapids, MI

ISOLATED GASTROCNEMIUS TIGHTNESS

BY CHRISTOPHER W. DIGIOVANNI, MD, RODERICK KUO, MD, NIRMAL TEJWANI, MD, ROBERT PRICE, MSME, SIGVARD T. HANSEN JR., MD, JOSEPH CZIERNECKI, MD, AND BRUCE J. SANGEORZAN, MD

Investigation performed at the Department of Orthopaedics, Harborview Medical Center, and the Seattle Veterans Affairs Medical Center, Seattle, Washington

ELSEVIER

Available online at www.sciencedirect.com
SCIENCE DIRECT®

Clinical Biomechanics 21 (2006) 59–66

CLINICAL BIOMECHANICS

www.elsevier.com/locate/clinbiomech

Novel biomechanics demonstrate gait dysfunction due to hamstring tightness

Kevin M. Cooney *, James O. Sanders, M. Cecilia Concha, Frank L. Buczek

Motion Analysis Laboratory, Shriners Hospitals for Children, 1645 West 8th Street, Erie PA 16505, USA

Received 27 January 2004; accepted 17 August 2005



BIOMECHANICS ACP

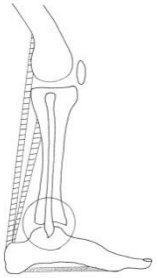



FOOT & ANKLE INTERNATIONAL

DOI: 10.3113/FAI.2008.0620

Gastrocnemius Recession as Treatment for Refractory Achilles Tendinopathy: A Case Report

Christopher E. Gentchos, MD; Donald R. Bohay, MD; John G. Anderson, MD
Grand Rapids, MI



FOOT & ANKLE INTERNATIONAL

DOI: 10.3113/FAI.2010.0019

Gastrocnemius Recession to Treat Isolated Foot Pain

John D. Maskill, MD; Donald R. Bohay, MD; John G. Anderson, MD
Grand Rapids, MI

FOOT & ANKLE INTERNATIONAL

The Effect on Ankle Dorsiflexion of Gastrocnemius Recession

Stephen J. Pinney, M.D.; Sigvard T. Hansen Jr., M.D.; Bruce J. Sangeorzan, M.D.
Sacramento, CA and Seattle, WA

BIOMECHANICS ACP



Available online at www.sciencedirect.com
SCIENCE DIRECT®
ELSEVIER
Clinical Biomechanics 21 (2006) 59–66
CLINICAL BIOMECHANICS
www.elsevier.com/locate/clinbiomech

Novel biomechanics demonstrate gait dysfunction due to hamstring tightness

Kevin M. Cooney *, James O. Sanders, M. Cecilia Concha, Frank L. Buczek

Motion Analysis Laboratory, Shriners Hospitals for Children, 1645 West 8th Street, Erie PA 16505, USA

Received 27 January 2004; accepted 17 August 2005

ISOLATED GASTROCNEMIUS TIGHTNESS

BY CHRISTOPHER W. DIGIOVANNI, MD, RODERICK KUO, MD, NIRMAL TEJWANI, MD, ROBERT PRICE, MSME, SIGVARD T. HANSEN JR., MD, JOSEPH CZIERNECKI, MD, AND BRUCE J. SANGEORZAN, MD

Investigation performed at the Department of Orthopaedics, Harborview Medical Center, and the Seattle Veterans Affairs Medical Center, Seattle, Washington

Clinical Biomechanics 24 (2009) 744–750

Contents lists available at ScienceDirect

Clinical Biomechanics

journal homepage: www.elsevier.com/locate/clinbiomech

Gastrocnemius tightness on joint angle and work of lower extremity during gait

Jia-Yuan You [a], Hsin-Min Lee [a], Hong-Ji Luo [b], Chwan-Chin Leu [b,c], Pen-Gang Cheng [d], Shyi-Kuen Wu [b,*]

[a] *Department of Physical Therapy, I-Shou University, Kaohsiung County, Taiwan*
[b] *Department of Physical Therapy, HungKuang University, Shalu, Taichung County, Taiwan*
[c] *Department of Physical Medicine and Rehabilitation, Taichung Hospital, Department of Health, Taiwan*
[d] *Department of Orthopedic Surgery, Kuang-Tien General Hospital, Taichung County, Taiwan*

EXTENSOR RECRUITMENT

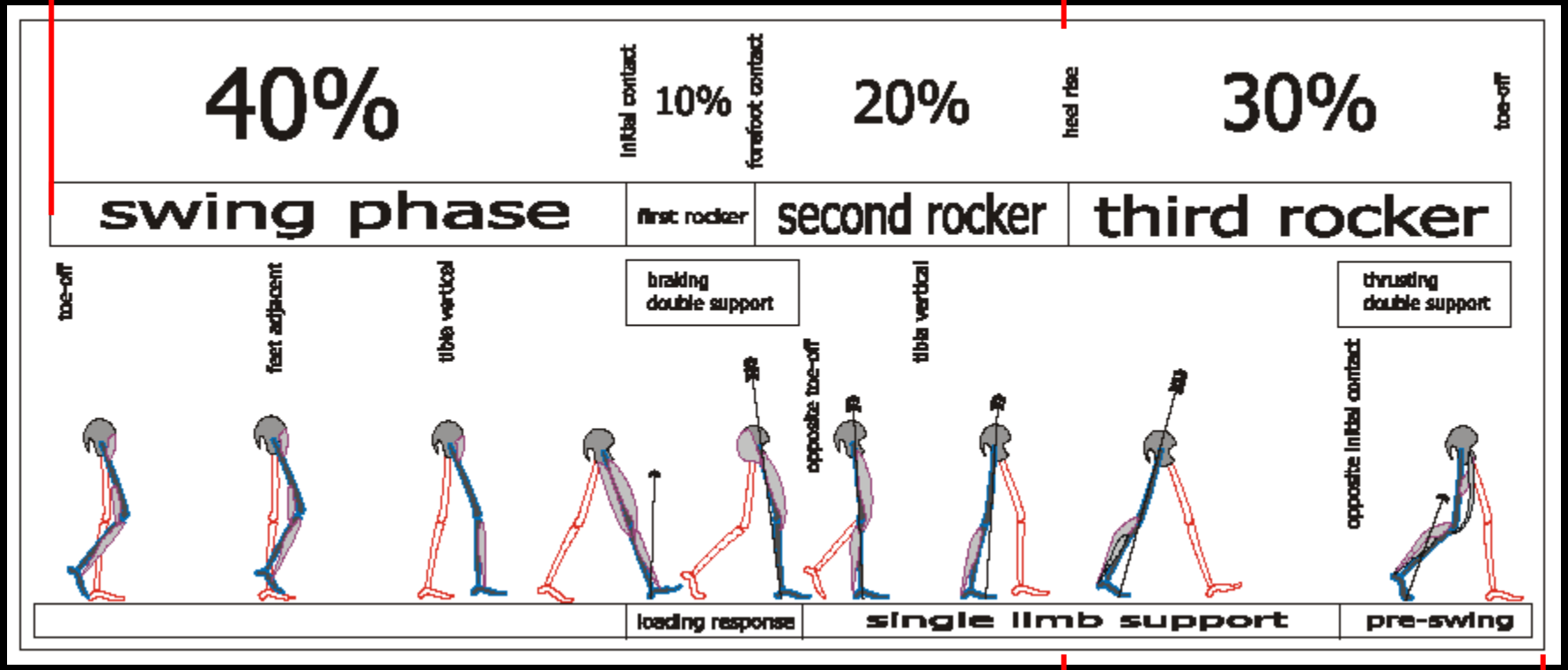

PROPULSION

based on Perry & Whittle

GASTROCNEMIUS
Hicks

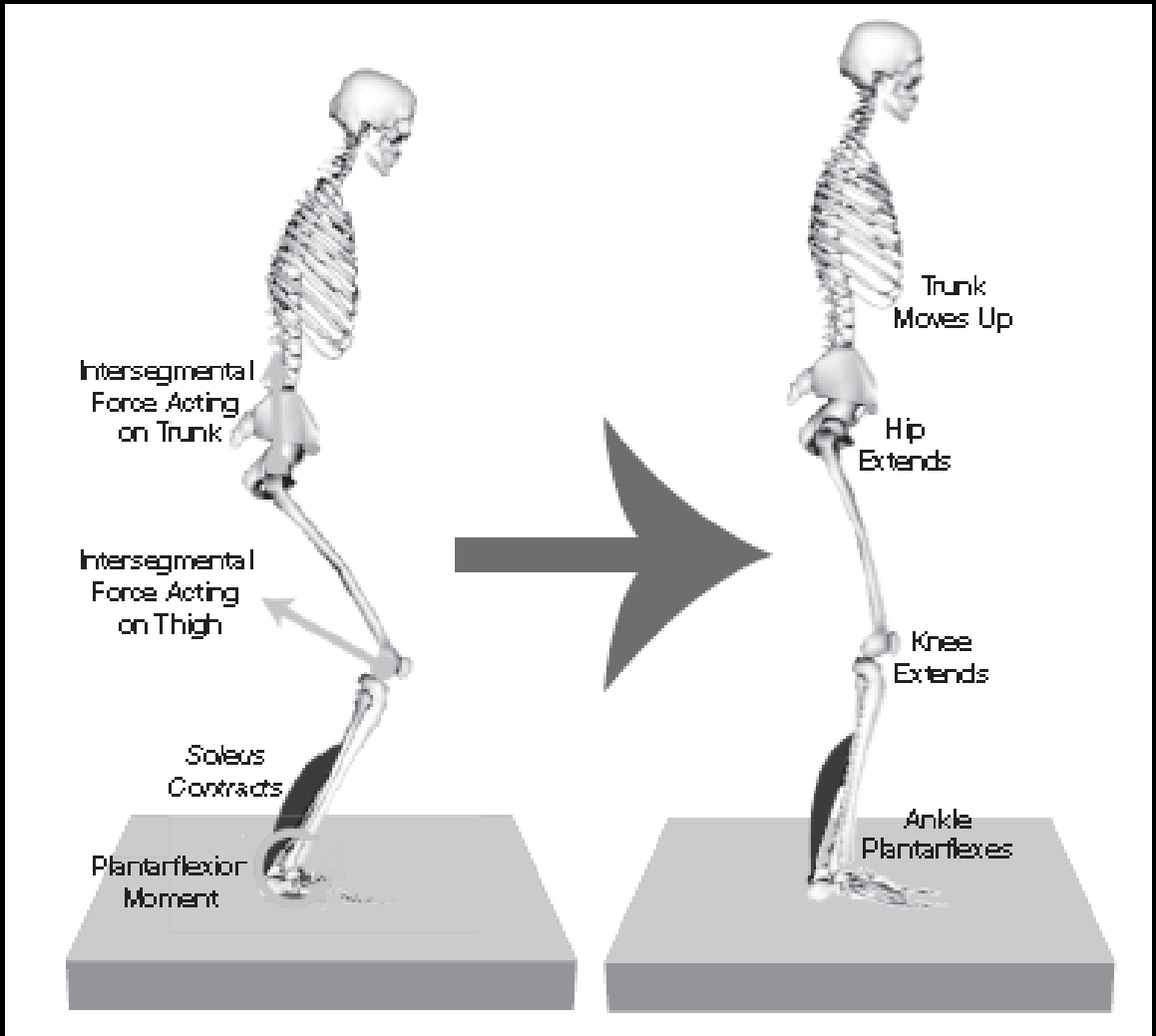

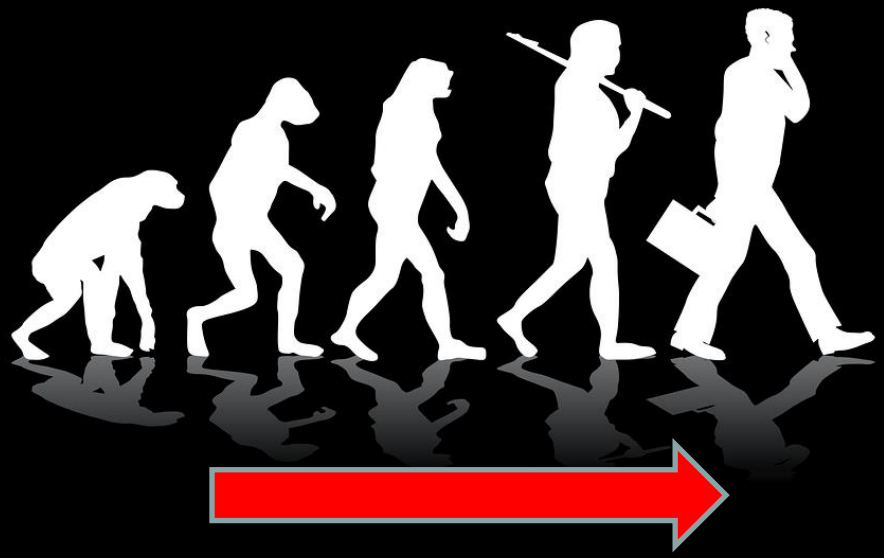

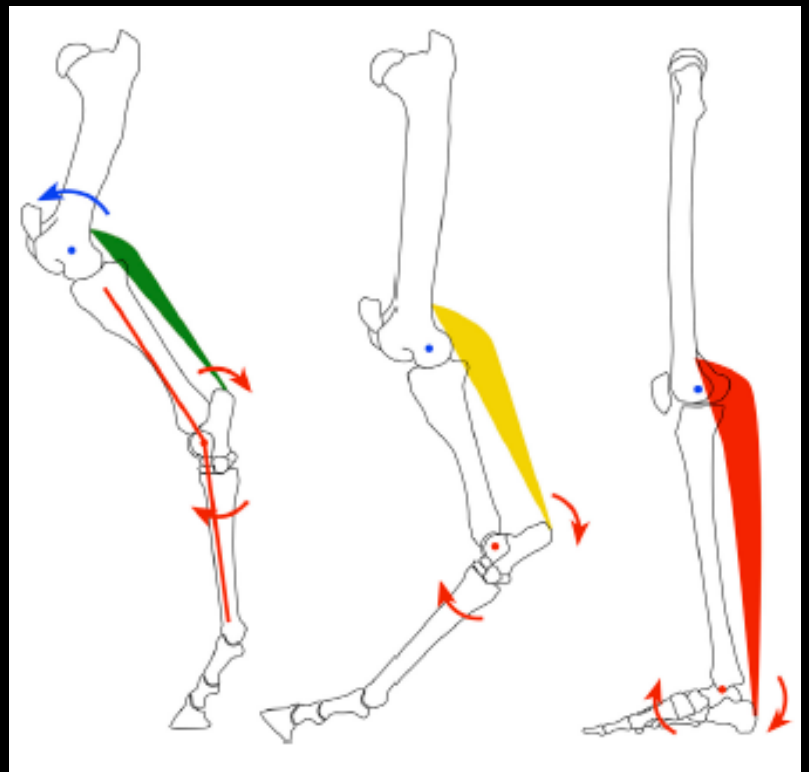

frontiers in Surgery

HYPOTHESIS AND THEORY
published: 27 July 2016
doi: 10.3389/fsurg.2016.00038

The Split Second Effect: The Mechanism of How Equinus Can Damage the Human Foot and Ankle

*James Amis**

Department of Orthopaedic Surgery, University of Cincinnati, Cincinnati, OH, USA

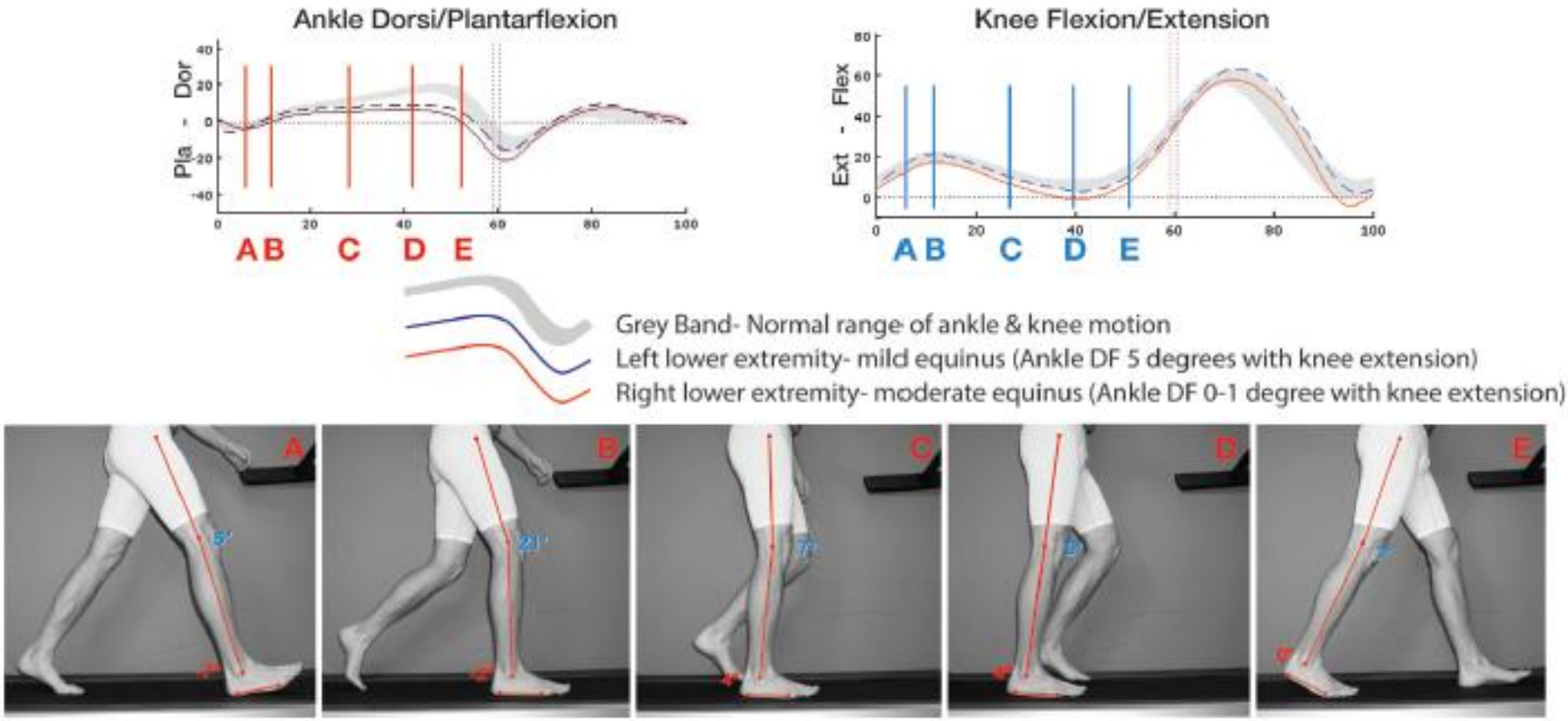

FIGURE 2 | Motion analysis compared to same subject on treadmill shot at 250 FPS of subject with bilateral equinus and history right plantar fasciitis who is asymptomatic at time of testing. At 28–45%, frames C–D depict the timing of the split second effect. There is accentuated knee extension and a failure of ankle dorsiflexion. This lack of normal ankle dorsiflexion motion gives rise to leveraged forces upon the foot and ankle.

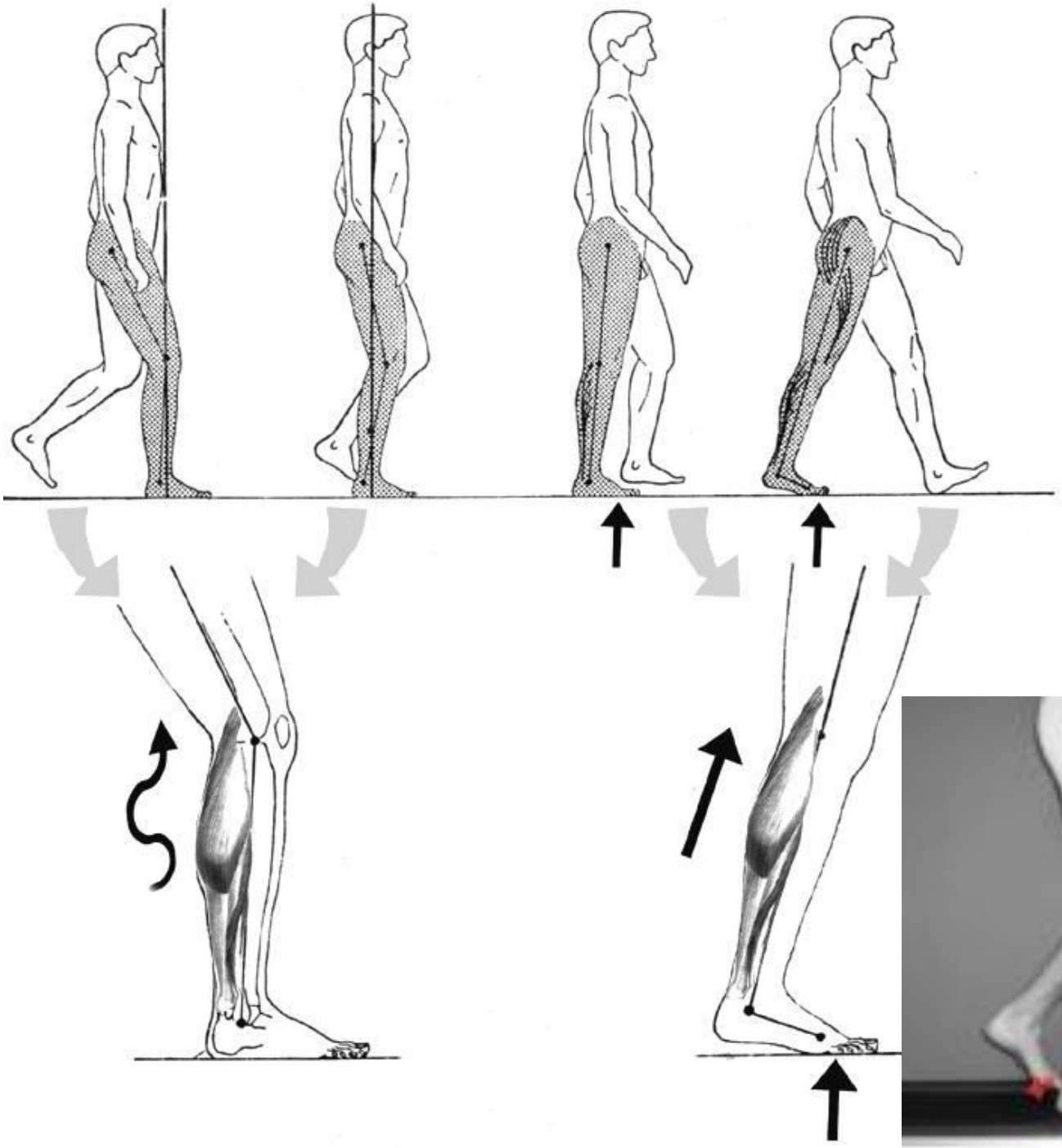

NILS SILFVERSKIÖLD
(1888–1957)

EQUINISM
HOW TO EXAMINE?

FOOT & ANKLE INTERNATIONAL

DOI: 10.3113/FAI.2008.0620

Gastrocnemius Recession as Treatment for Refractory Achilles Tendinopathy: A Case Report

Christopher E. Gentchos, MD; Donald R. Bohay, MD; John G. Anderson, MD
Grand Rapids, MI

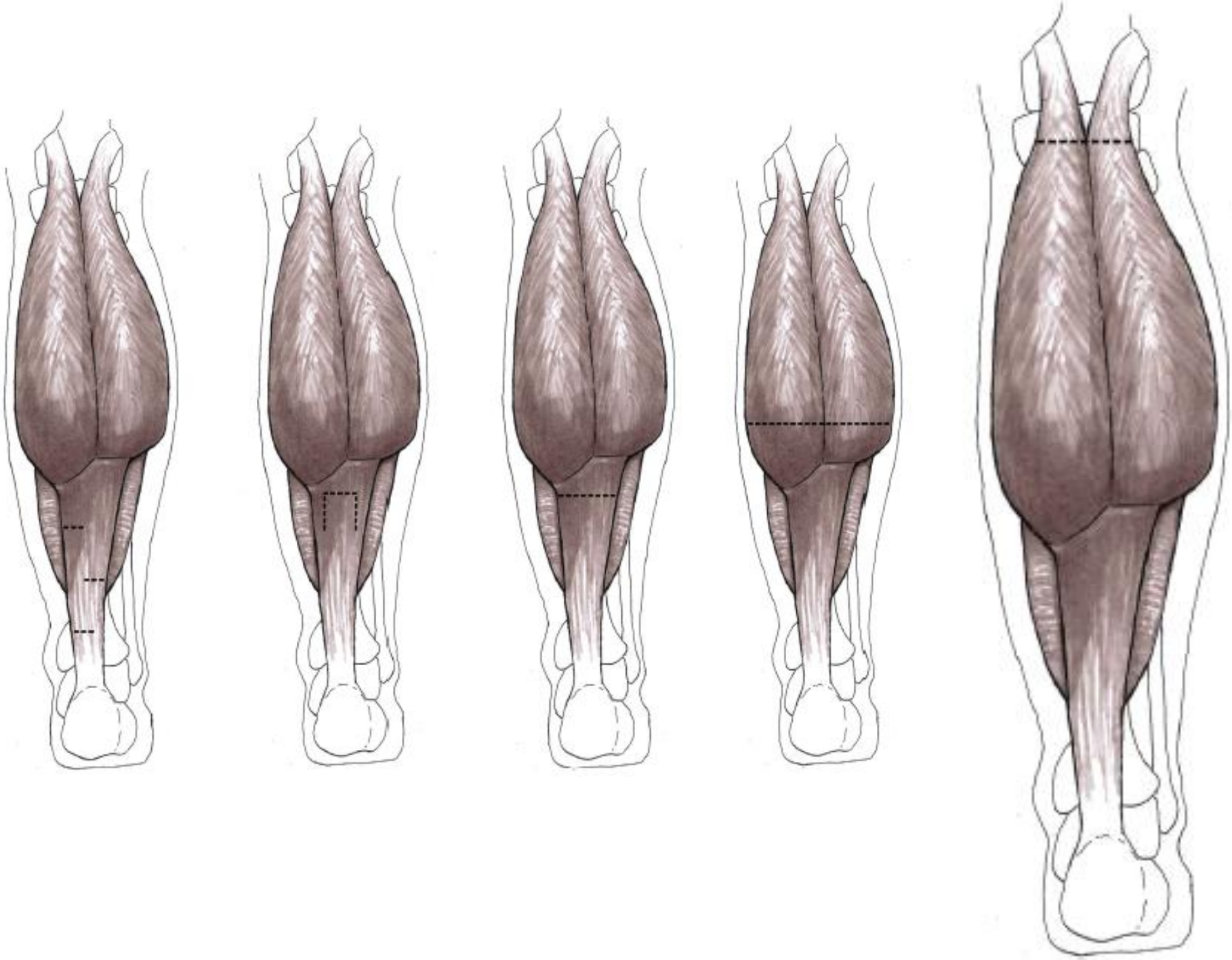

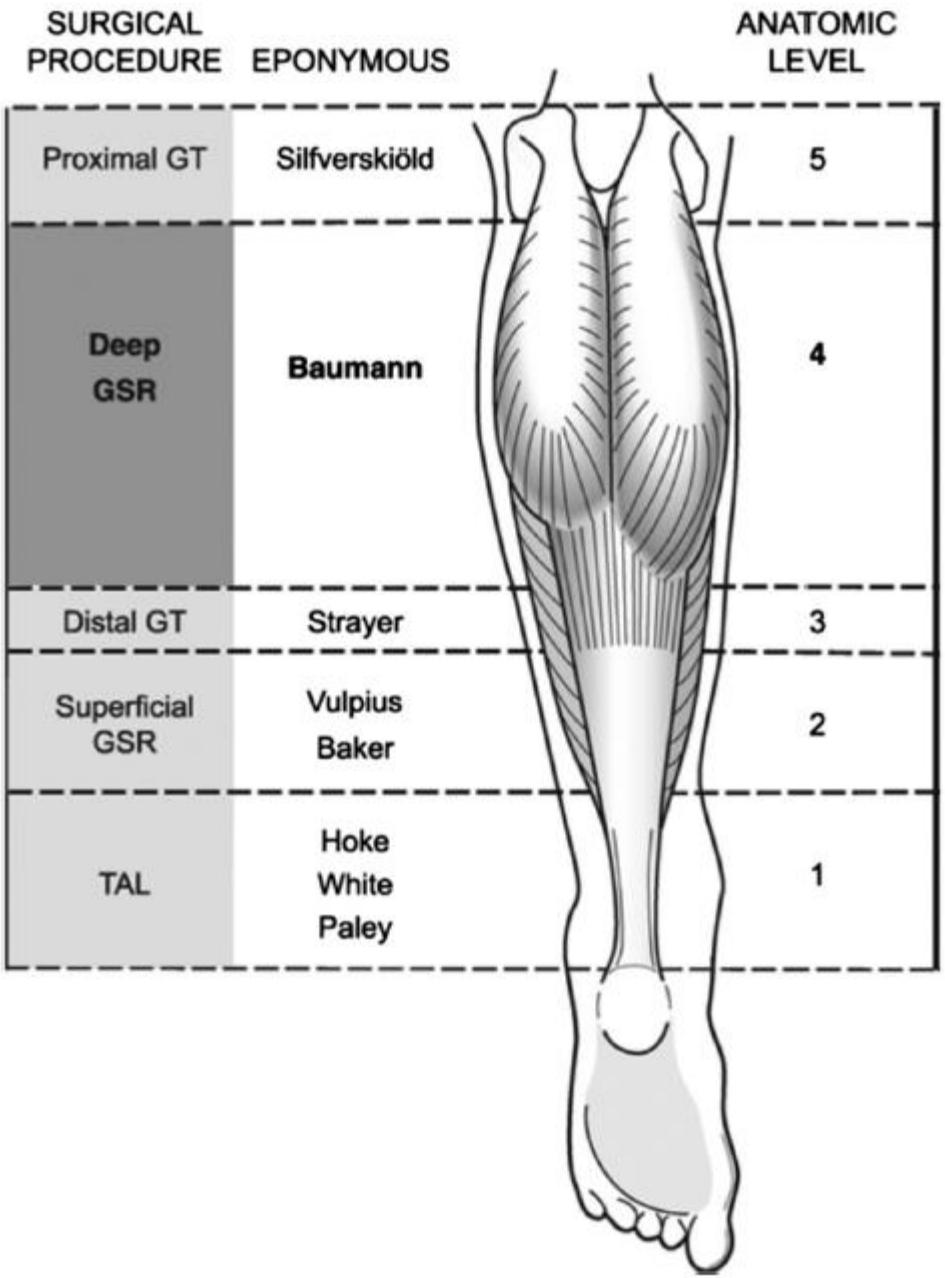
SURGICAL PROCEDURE
EPONYMOUS
ANATOMIC LEVEL
Proximal GT
Silfverskiöld
5
Deep GSR
Baumann
4
Distal GT
Strayer
3
Superficial GSR
Vulpius
Baker
2
TAL
Hoke
White
Paley
1

Barouk

Samuel and Pierre Barouk

Liberación de gastrocnemius

Resultados de una serie de 185 casos de APGM

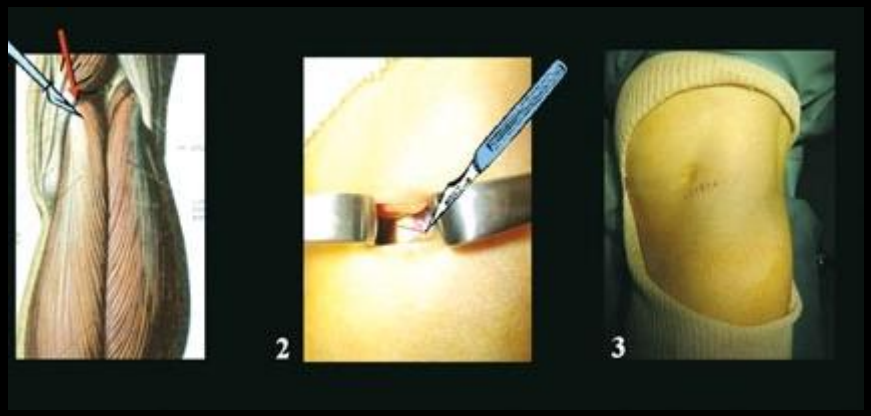

AOFAS spring meeting Toronto, 12-15 july 2007

THE DIFFERENTS TECHNIQUES OF GASTROCNEMIUS SURGICAL RELEASE

REUNION DE PRINTEMPS, SFMCP-AFCP, TOULOUSE, 8 JUIN 2006

P BAROUK, LS BAROUK, BORDEAUX

Section of the white fibers (Barouk)

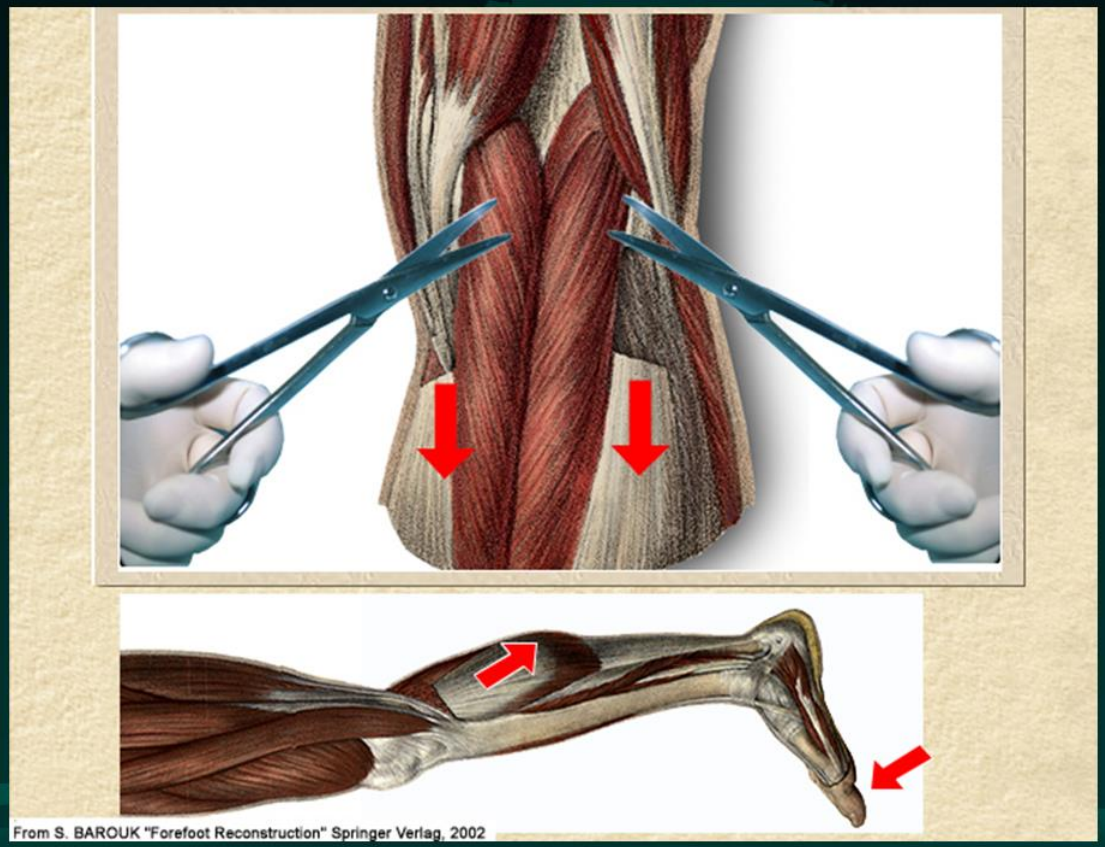

PROXIMAL RELEASE
BOTH GASTROCS?

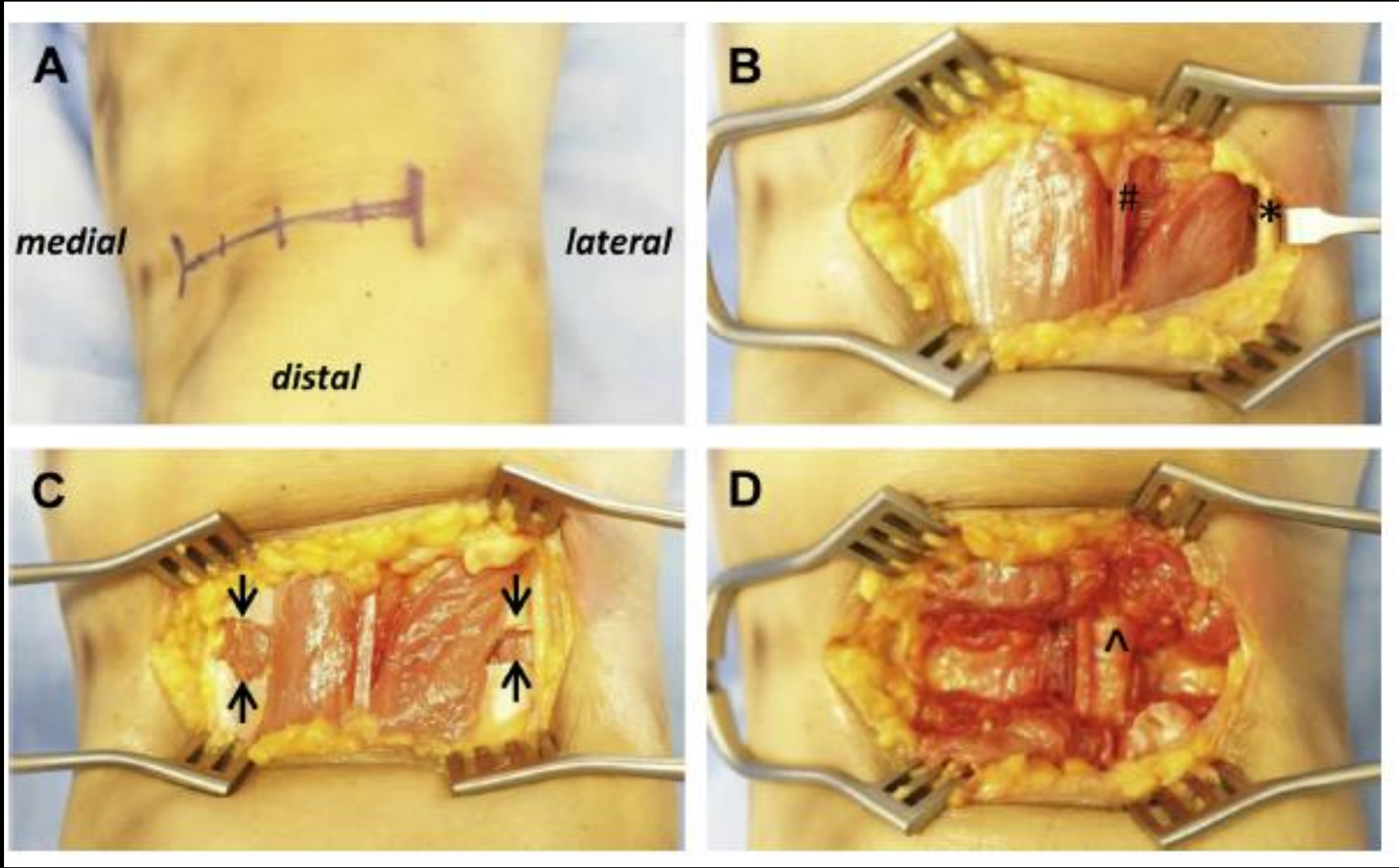


CASA LUGIO


London

The London
Foot & Ankle
Centre

FOOT & ANKLE INTERNATIONAL

DOI: 10.3113/FAI.2009.1202

Surgical Anatomy of the Proximal Release of the Gastrocnemius: A Cadaveric Study

Paul D. Hamilton, FRCS(Tr&Orth); Matthew Brown, MBBS; Neil Ferguson, MRCS; Miriam Adebibe, MBBS; Joanna Maggs, MBBS; Matthew Solan, FRCS(Tr&Orth)

Brighton, UK

Table 1: Medial and Lateral Sural Cutaneous Nerves in Relation to the Midline and Their Distance from the Tibial and Common Peroneal Origins, Respectively

	Medial cutaneous nerve	Lateral cutaneous nerve	Common peroneal nerve
Distance midline (average)	7 mm	23 mm	32 mm
Range	0–15 mm	10–42 mm	25–54 mm
Distance from origin	35 (18–60)	42 (2–70)	

Lateral



Medial



Muscle

Aponeurosis

Author(s) (year)	Type of Study	No. of Subjects (procedures)	Mean age (range)	Method	Mean Follow-up (range)	Outcome Measurement Tools	Outcome	Complications
Duthon et al. (2011)	Level IV (prospective case series)	14(17)	42 (20-64) yrs	Vulpius	(1-2 yrs)	AOFAS ankle-hindfoot, FFI, SF-12, MRI	AOFAS: from 71 (67-73) to 100 (90 to 100). FFI: from 39 (25 to 45) to 12 (10 to 19). SF-12 from 36 (33-44) to 51 (46-56). 11/14 able to resume previous sporting activity.	None
Gentchos et al. (2008)	Level V (case report)	1(1)	46 yrs	Vulpius	2 yrs	VAS, MRI, AOFAS	VAS from 10/10 to 0/10. AOFAS Hindfoot from 31 to 87. [illegible] asymptomatic 24 mo po.	None
Gurdezi et al. (2013)	Level IV (retrospective case series)	Noninsertional: 5(5)	48 (37-63) yrs	PMGR	30 mo (20 to 40 mo)	VAS, VISA-A, AOFAS ankle-hindfoot	AOFAS for from 61.8 (36-75) to 91.2 (63-100). VISA-A: from 34.8 (12-68) to 94 (87-100). VAS: from 7.8 (5-10) to 0.4 (0-1).	1 DVT (recovered uneventfully); 1 hypertrophic scar which had diminished at 2 yr follow up.
Kiewiet et al. (2013)	Level IV (retrospective case series)	8(8)	49.9 (-) yrs	Vulpius	34.6 mo (SD=18.1)	AOFAS ankle-hindfoot, SF-36, VAS, FFI, ROM	VAS improved from 7.3 (SD=1.7) to 1 (1.8). Post-op AOFAS score was 94.4 (SD=9.8).Mean FFI was 7.0 (0-36).	None
Laborde et al. (2011)	Level IV (retrospective case series)	24(28); 18 available for follow-up	57 (47 to 74) yrs	Vulpius	22 mo (6 to 60 mo)	VAS	Pain improved from 9/10 (7 to 10) to 1/10 (0 to 3) post-op. 6/18 had no pain at long term follow up.	2 stiffness, 1 weakness, 1 midfoot pain, 1 occasional calf pain, 1 unable to wear high heels. No wound complications.

FOOT & ANKLE INTERNATIONAL

DOI: 10.3113/FAI.2012.0014

Proximal Medial Gastrocnemius Release in the Treatment of Recalcitrant Plantar Fasciitis

Ali Abbassian, FRCS; Julie Kohls-Gatzoulis, FRCS; Matthew C. Solan, FRCS
Surrey and London, UK

International Orthopaedics (SICOT) (2013) 37:1845–1850
DOI 10.1007/s00264-013-2022-2

ORIGINAL PAPER

Chronic plantar fasciitis: Plantar fasciotomy versus gastrocnemius recession

Manuel Monteagudo · Ernesto Maceira · Virginia Garcia-Virto · Rafael Canosa

Received: 3 July 2013 / Accepted: 4 July 2013 / Published online: 21 August 2013

PROXIMAL MEDIAL GASTROCNEMIUS RELEASE

PROXIMAL MEDIAL GASTROCNEMIUS RELEASE

PROXIMAL MEDIAL GASTROCNEMIUS RELEASE

PROXIMAL MEDIAL GASTROCNEMIUS RELEASE

PROXIMAL MEDIAL GASTROCNEMIUS RELEASE

GOAL OF THIS STUDY

Analyze results of proximal medial gastrocnemius recession (PMGR) for the treatment of chronic recalcitrant plantar fasciitis

To compare isolated PMGR vs plantar fasciotomy in chronic plantar fasciitis

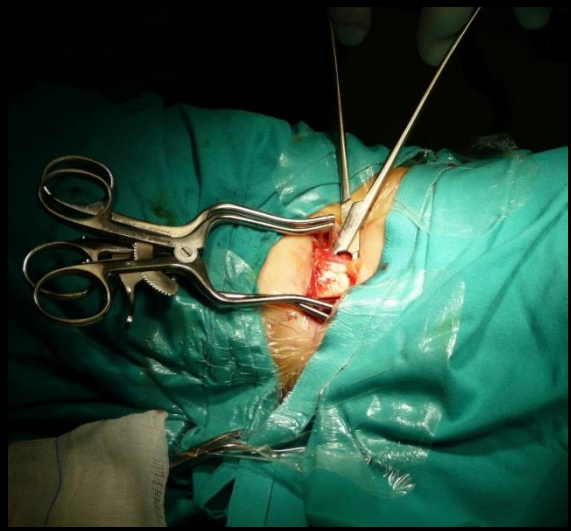

PATIENTS AND METHOD

Retrospective study

60 patients chronic recalcitrant plantar fasciitis
30 prox plantar fascitomies vs 30 PMGR

Groups matched for:
previous treatments, time symptoms at surgery
(>9 months, average 13 months)

PATIENTS AND METHOD

11 preop and postop variables studied

BMI, sudden weight gain/loss, occupation, previous treatments, sport practice, Silfverskiöld test, return to work, to sport, calf power, patient satisfaction, complications.

VAS, AOFASh, Likert

PMGR SURGICAL TECHNIQUE

WHERE TO LENGTHEN GASTROC?

PROXIMAL MEDIAL HEAD

FOOT & ANKLE INTERNATIONAL

DOI: 10.3113/FAI.2009.1202

Surgical Anatomy of the Proximal Release of the Gastrocnemius: A Cadaveric Study

Paul D. Hamilton, FRCS(Tr&Orth); Matthew Brown, MBBS; Neil Ferguson, MRCS; Miriam Adebibe, MBBS; Joanna Maggs, MBBS; Matthew Solan, FRCS(Tr&Orth)
Brighton, UK

LOCAL ANAESTHESIA, DAY PROCEDURE

POSTOPERATIVE PERIOD

Weightbearing as tolerated with use of crutches

Eccentric loading exercises from 3rd week

Progressive back to sport from 3rd week

POSTOPERATIVE PERIOD

Progressive back to sport:

from 3rd week

from 5th week

RESULTS

	PARTIAL PROXIMAL FASCIOTOMY 	**PROXIMAL MEDIAL GASTRO RELEASE** 
WORSENED POSTOPERATIVELY	2	0
COMFORTABLE FULL WEIGHTBEARING	4 WEEKS	2 DAYS
BETTER WITH RESPECT TO PREOP CONDITION	12 WEEKS (6-28)	5 WEEKS (1-16)
BACK TO WORK	3 MONTHS (1-6)	1 MONTH (0-3)
BACK TO SPORT	3 MONTHS (1-6)	1.5 MONTHS (0-4)

RESULTS

	PARTIAL PROXIMAL FASCIOTOMY 	**PROXIMAL MEDIAL GASTRO RELEASE** 
AOFASh PREOP	48	46
AOFASh POSTOP 1y	66	90
VAS PREOP (visual analogue scale)	8.1	8.2
VAS POSTOP 1y (visual analogue scale)	3.1	0.9

RESULTS

PATIENT SATISFACTION	PARTIAL PROXIMAL FASCIOTOMY 	PROXIMAL MEDIAL GASTRO RELEASE 
EXCELENT	10%	80%
GOOD	30%	10%
SATISFACTORY	20%	5%
POOR	40%	5%
RECOMMEND TO A FRIEND	45%	95%

COMPLICATIONS

COMPLICATIONS	PARTIAL PROXIMAL FASCIOTOMY 	PROXIMAL MEDIAL GASTRO RELEASE 
PAINFUL SCAR	5	0
NEUROLOGICAL	1	0
WOUND DEHISCENCE	1	1
INFECTION	1	0
COMPLEX REGIONAL PAIN SYNDROME	1	0





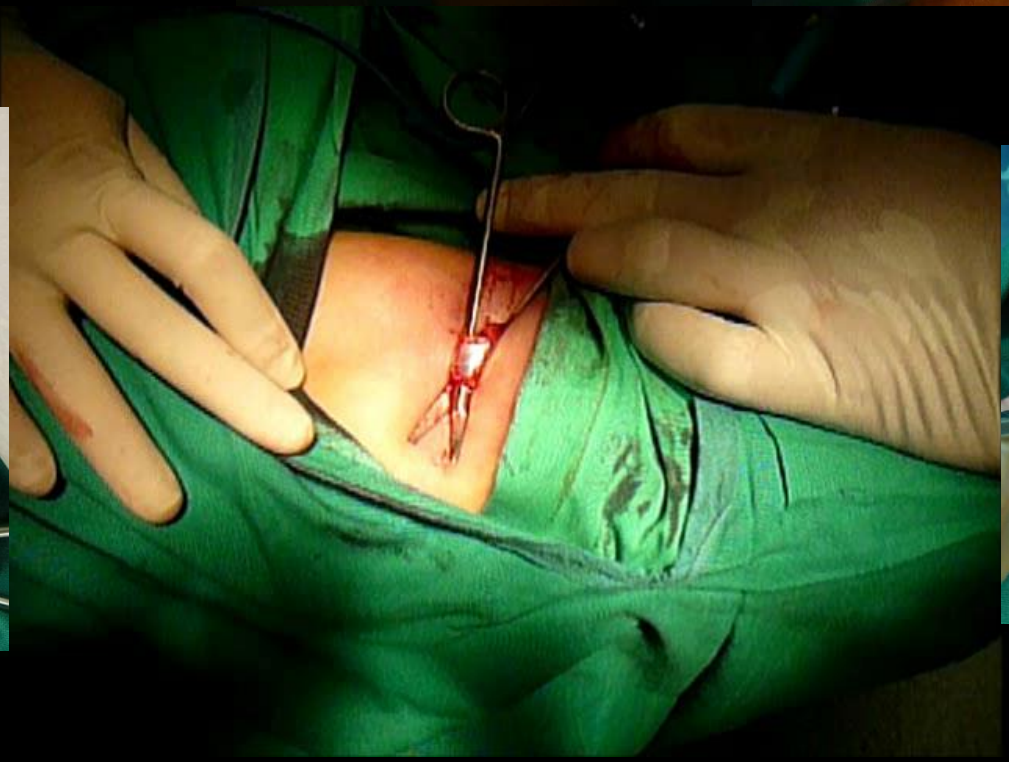


RESULTS

PREOP DURATION OF SYMPTOMS DOES NOT CORRELATE WITH OUTCOMES

NO DIFFERENCE IN OUTCOMES REGARDING PREVIOUS TREATMENTS

RESULTS

NONE OF PATIENTS WERE WORSE

44 PATIENTS WERE PAIN FREE AT 6 MONTHS

ALL SCALES SHOWED IMPROVEMENT

95% PATIENTS WERE SATISFIED

RESULTS

HOW DO RESULTS COMPARE WITH PROXIMAL PARTIAL FASCIOTOMY?



International Orthopaedics (SICOT)
DOI 10.1007/s00264-013-2022-2

ORIGINAL PAPER

Chronic plantar fasciitis: Plantar fasciotomy versus gastrocnemius recession

Manuel Monteagudo · Ernesto Maceira · Virginia Garcia-Virto · Rafael Canosa

DISCUSSION

WHAT IS OTHER GROUPS' EXPERIENCE WITH GASTROC RELEASE?

HIGHLY SATISFACTORY

FOOT & ANKLE INTERNATIONAL

DOI: 10.3113/FAI.2012.0014

Proximal Medial Gastrocnemius Release in the Treatment of Recalcitrant Plantar Fasciitis

Ali Abbassian, FRCS; Julie Kohls-Gatzoulis, FRCS; Matthew C. Solan, FRCS
Surrey and London, UK

DISCUSSION

LOSS OF CALF POWER?

NO, IT WORKS IN PRO ATHLETS

GASTROCNEMIUS SYNDROME


NO ERA CUENTO, NO
ASÍ HA QUEDADO EL PIE
DE PAU TRAS LA LESIÓN
11
BALE
11
32

Un calvario que no da tregua a Bale

TEMPORADA 2013-2014

1 22-09-2013
Calentamiento (RMA-GET)
Sobrecarga muscular en el muslo izquierdo.
2 Partidos | 6 Días

2 02-10-2013
Contractura muscular en el muslo de la pierna izquierda.
2 | 17

3 15-12-2013
Golpe en el gemelo (sóleo izquierdo).
2 | 22

4 25-01-2014
Sobrecarga del gemelo izquierdo.
3 | 14

TEMPORADA 2014-2015

5 20-10-2014
Rotura de grado II en el piramidal derecho (zona del glúteo).
3 | 16

6 10-04-2015
RVM-RMA
Sobrecarga muscular en el pie derecho.
1 | 6

7 18-04-2015
RMA-MAL
Lesión en el sóleo de la pierna izquierda.
3 | 15

TEMPORADA 2015-2016

8 15-09-2015
RMA-SHA
Lesión en el gemelo izquierdo.
4 | 15

9 19-10-2015
Lesión en el músculo sóleo de su pierna izquierda.
4 | 20

10 17-01-2016
SPO-RMA
Lesión en el músculo sóleo de su pierna derecha.
8 | 38

TEMPORADA 2016-2017

11 23-11-2016
SPO-RMA
Lesión traumática de los tendones peroneos de su tobillo derecho.
12 | 88

En cuatro temporadas
12 *lesiones*
44 *partidos perdidos*
257 *días de baja*

El galés se retira del campo tras la lesión sufrida ante el Barcelona

ANATOMÍA DEL TRÍCEPS SURAL
Gemelo externo (gastrocnemio)
Músculo **sóleo**
Pierna izquierda

12 23-04-2017
RMA-BAR
Lesión grado II en el sóleo de la pierna izquierda.

THE TAKE-HOME MESSAGE

SHORT GASTROCS SEEM TO PLAY AN IMPORTANT ROLE IN CHRONIC PLANTAR FASCIITIS

ISOLATED PROXIMAL-MEDIAL RECESSION IS SAFE AND EFFECTIVE

THE TAKE-HOME MESSAGE

BETTER RESULTS THAN FASCIOTOMY

FIRST SURGICAL OPTION IN CHRONIC PLANTAR FASCIITIS, WITH FASCIOTOMY ONLY CONSIDERED IF FAILURE

THINK OF GASTROC SYNDROME

Manuel Monteagudo

Orthopaedic Foot Ankle Surgery
Department Trauma and Orthopaedics
Hospital Universitario Quirónsalud
Facultad Medicina UEM Madrid
Spain
mmontyr@yahoo.com